

AMCoR

Asahikawa Medical University Repository <http://amcor.asahikawa-med.ac.jp/>

Parasites and Vectors (2015.3) 8:1–11.

The present situation and towards the prevention and control of neurocysticercosis on the tropical island, Bali, Indonesia

Toni Wandra, Kadek Swastika, Nyoman S Dharmawan, Ivan Elisabeth Purba, I Made Sudarmaja, Takahiko Yoshida, Yasuhito Sako, Munehiro Okamoto, Ni Luh Putu Eka Diarthini, Dewa Ayu Agus Sri Laksemi, Tetsuya Yanagida, Minoru Nakao, Akira Ito

REVIEW

Open Access

The present situation and towards the prevention and control of neurocysticercosis on the tropical island, Bali, Indonesia

Toni Wandra^{1†}, Kadek Swastika^{2,5,6†}, Nyoman S Dharmawan^{3†}, Ivan Elisabeth Purba¹, I Made Sudarmaja², Takahiko Yoshida⁴, Yasuhito Sako⁵, Munehiro Okamoto^{6†}, Ni Luh Putu Eka Diarthini², Dewa Ayu Agus Sri Laksemi², Tetsuya Yanagida^{5,7}, Minoru Nakao⁵ and Akira Ito^{5*†}

Abstract

Neurocysticercosis (NCC), which is caused by accidental ingestion of eggs of the pork tapeworm, *Taenia solium*, was common in Bali, Indonesia until the early 1990s. However, improved education on hygiene and sanitation, a move to keeping pigs indoors, and improvement of economic and living conditions have substantially reduced the occurrence of NCC in Bali. Since 2011, *T. solium* tapeworm carriers (*T. solium* taeniasis) and heavily infected pigs and dogs have exclusively been detected from villages in mountainous regions of northeastern Bali where NCC and ocular cysticercosis (OCC) cases have also been identified. In response to this continued area of high infection, a one-day workshop was convened to discuss how to prevent and control this potentially lethal zoonotic parasitic infection in Bali. This review presents an overview of the current status of *T. solium* taeniasis and cysticercosis in Indonesia and proposes a strategy for the prevention and control of this zoonosis in Bali.

Keywords: Neurocysticercosis, Cysticercosis, Taeniasis, Bali, Indonesia, Asia, Prevention, *Taenia solium*, *Taenia saginata*, *Taenia asiatica*, Parasitic zoonosis, Soil transmitted helminthiasis

Introduction

Taenia solium (also known as the pork tapeworm) and *Taenia saginata* (also known as the beef tapeworm) are human cestodes with a cosmopolitan distribution. These cestode infections result in both economic and public health impacts on affected communities [1-24]. Cysticercosis, which is caused by the larval stage of *T. solium*, is prevalent in humans and pigs mainly in many developing countries of the Americas, Africa and Asia but also in Europe as well [1-3,14,18,19,21,22,24]. Approximately 50 million people are suffering from neurocysticercosis (NCC) due to *T. solium* globally and more than 50,000 deaths per year are due to NCC [6,25]. Increased international travel and immigration are resulting in NCC being diagnosed and treated more frequently in non-endemic areas [5,26-33].

T. solium completes its life cycle using pig intermediate hosts and human definitive hosts (Figure 1). However, dogs can also become infected with cysticerci through the ingestion of parasite eggs [34]. Although it is conceived that humans were only obligatory intermediate host when this parasite emerged as a human parasite without involvement of pigs, humans are now paratenic hosts unless cannibalisms happen under extremely chaotic unusual conditions [35,36]. In humans, NCC resulting in epileptic seizures can be a life-threatening disease [7,12,16,25]. Taeniasis occurs through eating uncooked or undercooked pork contaminated with cysticerci, the metacestode stage of *T. solium*. Adult tapeworms then mature in the intestines of the infected person. Eggs from mature adult worms can infect pigs, dogs and humans resulting in cysticercosis. While ingesting infected pork is the most common way for a person to acquire *T. solium* taeniasis, eating dog meat does occur in parts of Asia including Indonesia, and may be responsible for some cases [34,36,37].

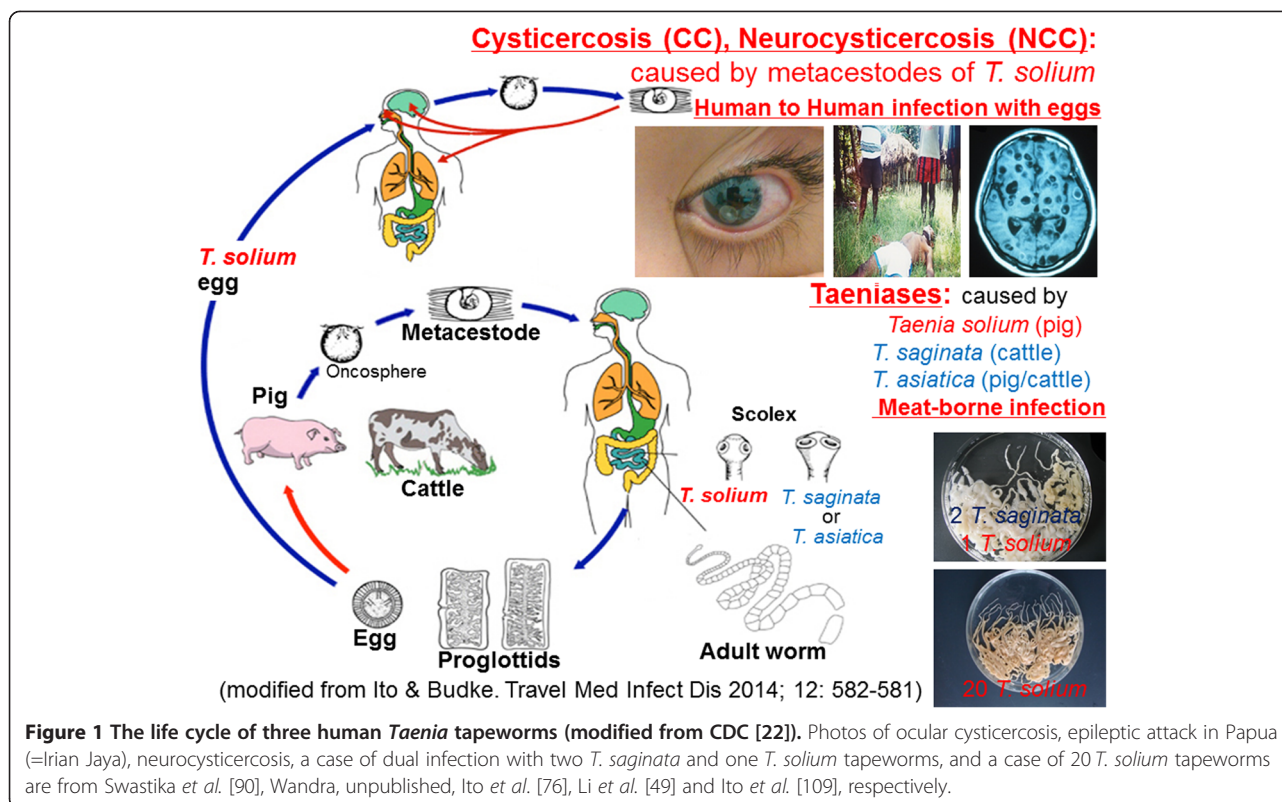
This review presents an overview of the current status of human taeniasis caused by *T. solium*, *T. saginata* and

* Correspondence: akiraito@asahikawa-med.ac.jp

†Equal contributors

⁵Department of Parasitology, Asahikawa Medical University, Asahikawa, Hokkaido, Japan

Full list of author information is available at the end of the article



Taenia asiatica and cysticercoses caused by *T. solium* (humans and livestock) and *Taenia hydatigena* (livestock) in Indonesia. A strategy for the prevention and control of this zoonosis in Bali is also proposed. Presented information is based on an ongoing joint project towards the control of human NCC in Indonesia which started in 1996 using several Japanese research funds. The topics addressed in this review are based on summaries from a one-day international workshop entitled "Strengthening of Prevention and Control of Taeniasis/Cysticercosis and Soil Transmitted Helminthiasis in Bali, Indonesia" held at the Faculty of Medicine, University of Udayana, Bali on 22 September 2014.

Review

Taeniasis caused by three human *Taenia* species in Indonesia

Three human *Taenia* species have been confirmed in Indonesia: *T. solium* has been reported mainly from Papua and Bali, *T. saginata* from Bali, and *T. asiatica* from Samosir island, North Sumatra [38,39]. The distribution of these parasites is not well documented in many Indonesian provinces. However, taeniasis and NCC have been reported from Lampung, Jakarta, East Java, East Nusa Tenggara, West Kalimantan, East Kalimantan, North Sulawesi, South Sulawesi, and South East Sulawesi (Figure 2) [38-43]. There is the concern that tapeworm carriers may establish new life cycles

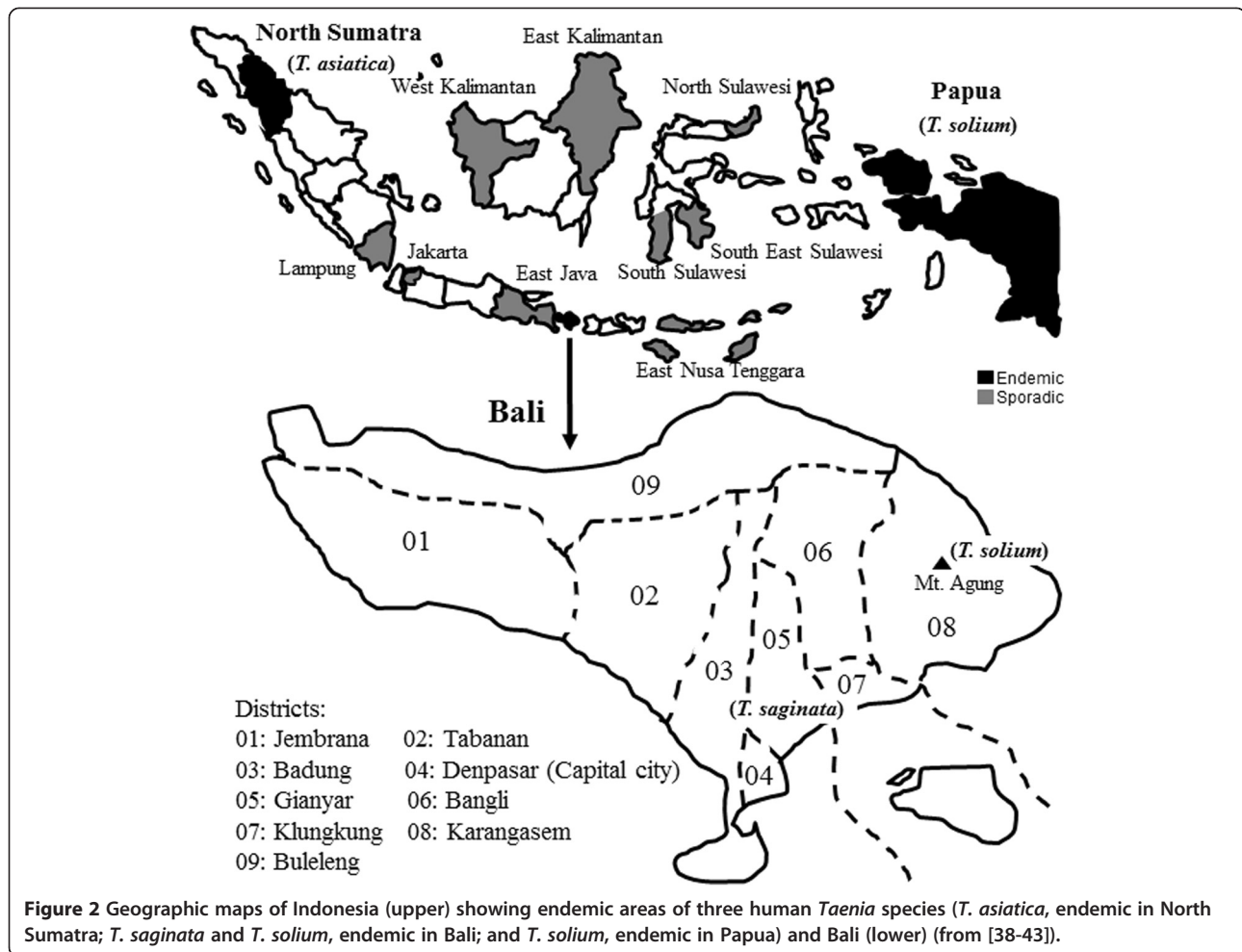via traveling to different islands. For example, if a *T. asiatica* carrier from Samosir Island were to visit Bali, there is the chance of establishing the *T. asiatica* life cycle in Bali. Variations in parasite distribution may also be due to cultural differences among the endemic areas (islands) [44,45]. For example, the Batak people in Samosir eat uncooked viscera of pigs but eat cooked pork, "sang-sang", whereas people in Bali eat uncooked pork "lawar" but do not eat uncooked viscera of pigs [43,46,47]. So, *T. asiatica* is still common in Samosir, whereas *T. solium* was common in Bali until the early 1990s, since cysticerci of *T. asiatica* develop in the viscera of pigs but not in meat.

In Thailand [48] and China [49] where *T. saginata*, *T. asiatica*, and *T. solium* are sympatrically distributed, hybrids or hybrid-derived tapeworms of *T. saginata* and *T. asiatica* have been confirmed by mitochondrial and nuclear DNA analyses [50-52]. Therefore, *T. saginata* and *T. asiatica* specimens collected in Indonesia should also be analyzed to determine whether or not hybridization is occurring.

Cysticercosis in Indonesia

Papua (Irian Jaya): *T. solium* taeniasis and NCC highly endemic

Papua (formerly Irian Jaya) is a known high endemic area for NCC [39,53-65]. Outbreaks of NCC in Papua had been reported since the early 1970s, with historical reports briefly



reviewed by Simanjuntak *et al.* [38]. The Indonesian Government started a 10-year project to control taeniasis and NCC in Papua from 1990 [39,41,53-65]. Recent studies have revealed that Papua is still highly endemic with most of the NCC cases also presenting with subcutaneous cysticercosis (Figure 3) [41,43,58-63]. Serology is important for the early diagnosis and treatment of asymptomatic NCC cases as well as to identify infected pigs and dogs [34,41,61], and remove them from the food chain. Results from a commercially available ELISA [66] without any direct evidence of infection should be re-evaluated by immunoblot using purified antigens [67-78], since cross-reactions may occur among the various *Taenia* spp. that infect pigs (see below) [36,37]. Optimally, serological tools should be evaluated against pig necropsy findings as is currently underway in Karangasem, Bali (Dharmawan *et al.* unpublished).

Bali: *T. saginata* and *T. solium* taeniasis and NCC

Prior to the early 1990s, NCC was considered a fairly common disease in Bali [41,79-91]. However, health education programmes have dramatically reduced the number of cases in the last twenty-five years. NCC

cases were reported sporadically and *T. solium* taeniasis cases had not been detected via field surveys since 2002 [43,46,47,68,89]: From 2002 until 2010, all *Taenia* tapeworms collected through epidemiological studies were identified as *T. saginata*, with the majority of infections occurring in the district of Gianyar (Tables 1 and 2, Figures 2 and 4). Detection of taeniasis carriers was based on questionnaire and stool examination for eggs of *Taenia* and soil transmitted helminths (STHs). Eggs of *Ascaris*, *Trichuris*, and hookworms are more common everywhere in Bali (Wandra *et al.* unpublished). Therefore, the project on taeniasis is one part of STH surveys with medication of STH carriers.

When tapeworm carriers in Gianyar were treated with praziquantel (PZQ) (15 mg/kg BW), one individual had an epileptic seizure within half a day of receiving the drug. This patient was later confirmed as having previously asymptomatic NCC, which became symptomatic after receiving PZQ [89,92]. This case was also confirmed serologically to be cysticercosis [89]. If a lower dose of PZQ (5 mg/kg BW) which is sufficient for expulsion of tapeworms but not sufficient for damaging



Figure 3 Subcutaneous cysticercosis patient in Papua. This patient was often attacked by epileptic seizures [41,43,58-63].

cysticerci was administered [92], this veiled asymptomatic NCC could not become symptomatic, and we could not find dual infections with *T. saginata* taeniasis and *T. solium* NCC. It is believed that *T. saginata* infections in people were due to consumption of undercooked beef “lawar” contaminated with cysticerci. In contrast, it is believed that the NCC case was due to accidental ingestion of *T. solium* eggs from a tapeworm carrier who had been infected in a *T. solium* endemic area of Bali.

Bali (eastern slope of Mt. Agung in Karangasem): *T. solium* tapeworm carriers and infected pigs

In December 2010, a case of ocular cysticercosis (OCC) was confirmed in a 9-year-old girl (Figure 1) from a remote village in the Kubu sub-district of Karangasem (Figure 5) [90]. The village is located on the eastern slope of Bali’s highest mountain, Mt. Agung (altitude 3,132 m). In highly endemic areas in other countries, it is not so easy to detect tapeworm carriers as found in this small area (Table 1) [11,93-96]. A field survey carried out in January 2011 in the patient’s village and neighbouring villages revealed three individuals with *T. solium* taeniasis (Table 1) [90,93]. Two cases (a 4-year-

old girl and a 38-year-old man) were from the same village where the original OCC case was identified. The third case (35-year-old woman) was from a neighbouring village. Table 1 summarizes human taeniasis prevalence data collected in Karangasem (Kubu sub-district) from January 2011 to September 2014 and Gianyar (Sukawati sub-district) from 2002 to 2014. In total, six *T. solium* taeniasis cases (6/265, 2.26%) were detected in 2013, and additional two cases (2/138, 1.45%) were identified in 2014 in Karangasem (Swastika *et al.* unpublished).

In addition to human taeniasis cases, pigs and dogs with cysticerci have been found in this region (Figure 6). Thus far, all tapeworms expelled in Gianyar have been confirmed to be *T. saginata* by molecular analysis. In contrast, all tapeworms except for one expelled in villages in the Kubu sub-district have been *T. solium*. The one *T. saginata* specimen was obtained from an individual living in a more urban village and is speculated to have been an imported case from Gianyar. The fact that taeniasis cases due to *T. solium* have, thus far, all been exclusively from mountainous villages strongly suggests that contaminated pork is being consumed within these villages, but is not being sold to other regions. It strongly suggests that *T. solium* is still exclusively spreading in relatively small rural and remote mountainous villages in Karangasem.

The weather on the eastern slope of Mt. Agung differs from other areas in Bali, with little grass available during the dry season (Figure 5). Since all climbing routes to Mt. Agung are located on the western side of the mountain, the endemic villages are almost completely isolated. However, residents of this area often go to the local capital city of Denpasar or other districts to find work, which has the potential to result in an outbreak of NCC in these non-endemic areas [85,97-100].

Modern tools for identification of taeniasis carriers, cysticercosis patients, and cysticercosis in pigs

Taeniasis

Multiplex PCR was first used to identify parasites that were expelled after chemotherapeutic therapy, since the expelled tapeworms were often damaged and without a scolex, which is useful for the differentiation of *T. solium* with hooklets on the scolex from two other *T. saginata*-like species without hooklets. As eggs of *Taenia* spp. are impossible to be identified morphologically, molecular analysis using even a single egg in feces [101] is essential for the identification of the *Taenia* species. While multiplex PCR was useful for differentiation of adult worms [75,76,97-100], it was not optimal for the detection of DNA in stool samples. It is important to be able to detect parasite-specific DNA in stool samples to avoid inducing epileptic seizures in taeniasis cases that also have asymptomatic NCC [88,89]. Recently, loop mediated isothermal amplification (LAMP) and copro-LAMP have been utilized to obtain real-time

Table 1 Summarized data of taeniasis cases and seroprevalence of cysticercosis by district in Bali, 2002–2014 [40,43,47,88,89]

District (Year)	No. of <i>T. saginata</i> taeniasis cases	No. of <i>T. solium</i> taeniasis cases	Seroprevalence of cysticercosis in humans (%)	Seroprevalence of cysticercosis in pigs (%)
Gianyar (2002)	32	-	0.8 (1/125)	NA
Gianyar (2004)	14	-	0.0 (0/46)	NA
Gianyar (2005)	5	-	0.0 (0/13)	NA
Gianyar (2006)	2	-	0.0 (0/39)	NA
Gianyar (2007)	3	-	4.2 (1/24)	NA
Gianyar (2008)	4	-	NA	NA
Gianyar (2009)	7	-	NA	NA
Gianyar (2010)	18	-	0.0 (0/24)	NA
Gianyar (2011)	9	-	5.4 (8/147)	NA
Gianyar (Jan 2013)	6	-	0.1 (1/13)	NA
Gianyar (Sept 2013)	9	-	7.1 (1/14)	NA
Gianyar (2014)	4	-	NA	NA
Badung (2004)	1	-	0.0 (0/91)	NA
Denpasar (2004)	9	-	0.0 (0/49)	NA
Denpasar (2005)	2	-	0.0 (0/16)	NA
Denpasar (2010)	3	-	0.0 (0/54)	NA
Karangasem (urban area, 2006)	1	-	2.8 (1/36)	NA
Bangli (2007)	0	-	0.0 (0/32)	NA
Tabanan (2008)	0	-	0.0 (0/42)	NA
Jembrana (2008)	0	-	0.0 (0/84)	NA
Klungkung (2009)	0	-	0.0 (0/100)	NA
Buleleng (2009)	0	-	0.0 (0/47)	NA
Karangasem (rural area, 2011)	-	3	6.3 (11/175)	11.6 (5/64)
Karangasem (Jan. 2013)	-	6	5.1 (11/214)	18.0 (31/164)
Karangasem (Sept. 2013)	-	2*	4.2(5/118)*	6.9 (7/101)*
Karangasem (2014)	-	2*	#	#
Total	129	13	2.6 (38/1489)	13.1 (43/329)

NA: no data available.

*in confirmation.

*Swastika et al. unpublished.

identifications of *Taenia* species [102-104]. Molecular identification using a haplotype network of mitochondrial gene (s) is another useful tool for identifying the infecting species [105,106].

Cysticercoses in pigs and dogs

Pigs confirmed to be naturally infected with *T. solium* show antibody responses to antigens purified by preparative iso-

electric focusing [69,70] and recombinant antigens [67,71,107,108]. Similar results are also achieved using a more simple and cheap, cation-exchange chromatography [67]. Antibody responses in pigs in endemic areas have been tested using an ELISA with tests read by looking for a colour change with the naked eye (Dharmawan et al. unpublished) [36,37]. The majority of pigs showing strong positive responses were confirmed to be infected

Table 2 Neurocysticercosis (NCC) in Gianyar district, Bali, 2003, 2007, and 2010 [40,43,47,88,89]

Area/Hospital (year)	Diagnose	No. of case
Gianyar/Sanglah Hosp. (2003)	NCC	1 (disseminated cysticercosis)
Gianyar (2007)	NCC (dual infection)	1 (with <i>T. saginata</i> taeniasis)
Gianyar (2010)	NCC(1)/cysticercosis (2)	3 (with <i>T. saginata</i> taeniasis) (dual infection)



Figure 4 *T. saginata* (a, b, c) expelled after anamnesis and microscopy in Gianyar. One long *T. saginata* tapeworm expelled from one tapeworm carrier (a), *T. saginata* tapeworms expelled from wife and husband and kept in bottles (b), and *T. saginata* tapeworms expelled from 8 carriers during one day survey (c).

with *T. solium* cysticerci, with the remainder infected with *T. hydatigena*. Pigs infected with *T. hydatigena* tended to have a much weaker positive test than pigs infected with *T. solium* (Dharmawan et al. unpublished). Cysticercoses in pigs co-infected with these two species should also be identified due to the risk of human NCC [70,109].

Available serology is also applicable to dogs in endemic areas [34]. Residents of villages in Kubu are known to eat dog meat, with local dogs confirmed to be infected with *T. solium*. Therefore, studies are needed to evaluate the role of dogs in the *T. solium* life cycle. In addition, the role of dogs should also be included in local education programmes [34].

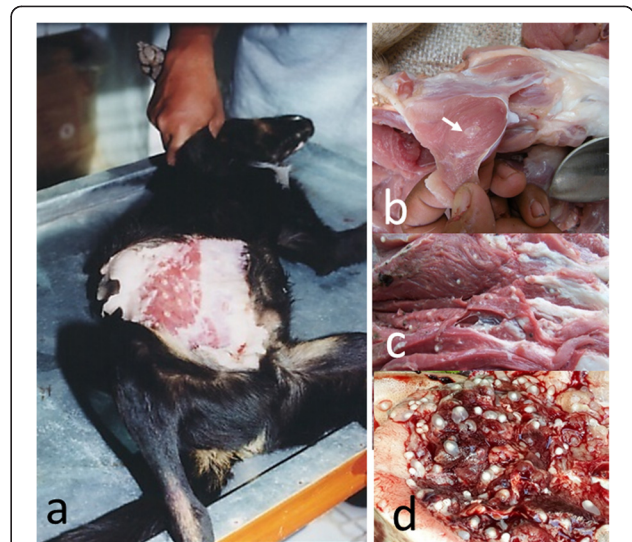


Figure 6 Cysticerci of *T. solium* in one dog (a) and three pigs (b, c, d). One dog full of cysticerci (a) [34] and pigs contaminated with light (b), middle (c) and heavy (d) infections with cysticerci confirmed based on the naked eye-ELISA (Dharmawan et al. unpublished) [36,67,69,70].

International meetings on NCC in Bali

NCC was discussed at two International meetings on “Recent Progress in Parasitology” (August 2007) and “Neurological Diseases” (November 2009) held in Denpasar. The meetings were aimed at both clinicians and medical researchers. These meetings were in addition to a symposium on cestode zoonoses in Asia which has been held almost every year since 2000 in Thailand, and in Japan (2006), and in Korea (2007) [39,60,64,68,72,73,76-78,89,98,99,110-112]. On 22 September 2014, a workshop focusing exclusively on the control of taeniasis and NCC was held at the University



Figure 5 Landscape of the eastern slope of Mt. Agung (a, b) and water tanks for dry season (c, d, e). Dry season in September 2014 (a) and rainy season in January 2012 (b). Right half of the mountain (a): the eastern slope is completely brown. Southern slope in the left half is better in green, Western slope is completely green for all seasons (not shown).

of Udayana. The meeting was aimed at personnel working in medicine, veterinary medicine, public health, meat inspection, and the local government.

Towards control of NCC

Since 2011, *T. solium* in Bali has been maintained in a small area on the eastern slope of Mt. Agung. However, the prevalence and distribution of NCC seems to be increasing through immigration of individuals from this endemic area to the Denpasar metropolitan area. As shown in Figure 5, during the dry season, villagers have difficulty in obtaining safe drinking water and feed for their pigs. Therefore, pigs are often left to roam and scavenge during the dry season. In addition, during the dry season, local inhabitants often go to Denpasar or other larger cities to find work, increasing the risk of bringing *T. solium* to currently non-endemic locations. This phenomenon has also been seen in refugee villages along the Thailand-Myanmar border [48], and in Tibetan communities in Sichuan Province, China [49].

Due to the stigma attached to being a tapeworm carrier, most people are not willing to submit a stool sample for evaluation. It is also difficult to change local food consumption behavior *lawar*, a traditional food made with uncooked beef or pork is commonly consumed in the endemic areas of Bali. In Gianyar district, while the majority of people stop eating *lawar* after being diagnosed with tapeworm(s), it is not uncommon for these same individuals to start eating *lawar* again 1–3 months later (Figure 2) [46]. Based on questionnaires administered to residents of a *T. solium* endemic area in Karangasem district, 29% (18/62) of families have no sanitary facilities and people defecate in the garden, 83.9% (40/46) of pig owners keep their pigs in a fenced field, 10.9% (5/46) keep their pigs in an open common pasture, and 2.2% (1/46) allow their pigs to roam free [43]. Based on direct observations, environmental sanitation and personal hygiene is also very poor in this region.

In Bali, infection with *T. saginata* is believed to be related to consumption of beef *lawar*. Quality control of beef and pork is difficult due to the presence of illegal slaughterhouses in addition to a limited number of official meat inspectors. In study conducted in 2002–2004, three of 56 identified tapeworm carriers were *lawar* sellers who acknowledged suffering from *T. saginata* taeniasis for 1–10 years. Several other taeniasis carriers indicated that they bought *lawar* from these sellers (Wandra, personal communication).

The health sector budget allocated by the central government for taeniasis control is very limited due to the presence of other important communicable diseases and the need for resources to be channeled into the country's environmental health programme. There is also very

little funding to pursue control measures at the provincial and district levels. Similarly, *T. solium* has a low priority for the agricultural sector and, therefore, receives little to no funding from this sector.

Opportunities

Approximately more or less than 3 million travelers visiting the island of Bali every year may be at risk for acquiring *T. solium* cysticercosis. Fortunately, the identified highly endemic areas are not commonly visited by tourists. Due to the limited geographic distribution of the parasite, it may be possible to control and eradicate *T. solium* from Bali given the appropriate resources. Successful control of *T. solium* transmission on Bali could then be used as a model for other islands in Indonesia and beyond.

Recommendations

Based on recommendations put forth during the 2014 workshop and taking into consideration local cultural practices, the typical education level of local inhabitants, socio-economics, sanitation and personal hygiene conditions in the endemic area of Bali, the following prevention and control activities were recommended.

1. Combine the prevention and control of taeniasis and NCC with the prevention and control of STHs. As STHs including *Ascaris*, *Trichuris* and hookworms etc. are more common than *Taenia*, detection of taeniasis carriers are one part of STH surveys. All STH carriers have been medicated through all taeniasis projects in Indonesia.
2. Review and strengthen the 'legal aspects' for the prevention and control of taeniasis and NCC at the provincial, district, and local level. This would include standardizing policies and methods for the distribution of guidelines for the prevention and control of taeniasis and NCC. It would also include better law enforcement to prevent the occurrence of illegal slaughterhouses.
3. Strengthen buy-in of policy makers, stake holders, professional organizations, universities, NGOs, and members of the private sector.
4. Intensify active and passive surveillance, with prompt treatment of identified tapeworm carriers.
5. Conduct periodic health inspection of *lawar* sellers and their family members.
6. Conduct health investigations of family members and neighbours of newly diagnosed NCC patients.
7. Improve public health education focusing on personal hygiene, environmental sanitation, and practices related to pig and cattle rearing, with an emphasis on primary school-aged children.
8. Develop and distribute IEC media on taeniasis and NCC prevention that has been translated into the

local languages/dialects and edited to be socially and culturally appropriate.

9. Further invest in local health education programmes by training additional health workers and then having them participate in a train-the-trainer programme.
10. Strengthen the epidemiological surveillance of taeniasis and NCC in Bali by using validated diagnostic tools.
11. Provide additional funding for the prevention and control of taeniasis and NCC.
12. Improve the meat inspection system and conduct studies to determine the prevalence and distribution of infected animals.
13. Encourage political commitment and inter-sectoral collaboration at the local, national, and international levels.
14. Put in place a system to monitor and evaluate the taeniasis and NCC prevention and control programme in Bali.

Vaccination of pigs is an additional highly promising action plan [113–117]. Detection of pigs contaminated with cysticerci of *T. solium* by simple but reliable serology (Dharmawan *et al.* unpublished) [36,37,67,70], and simultaneous vaccinations of all pigs by oral treatment with oxfendazole (30 mg/kg) at the same time as the booster vaccination [116,117] may be the best. However, through sustainable education which almost succeeded in control of taeniasis and NCC in Bali over the past two decades, further sustainable education and improvement of living environment and treatment of *T. solium* taeniasis carriers, especially in endemic area, Karangasem, may be sufficient for successful control of taeniasis and NCC in Bali. If the budget for the control of NCC is big enough to introduce vaccination trials, it is the best.

In order to strengthen the NCC prevention and control programme in Bali, a Research Center at University of Udayana will be established. University of Udayana was selected due to its hospital's clinical experience with the treatment of NCC as well at the presence of faculties of medicine and veterinary medicine. This new research center will complement the current work being conducted on the prevention and control of other neglected tropical diseases, i.e. rabies in Bali.

Conclusions

An overview of the current status of *T. solium* taeniasis and cysticercosis in Indonesia reveals the importance of a strategy for the prevention and control of this zoonosis in Bali.

Competing interests

The authors declare that they have no competing interests.

Authors' contributions

AI and TW launched the idea for writing this MS. AI, TW, KS, NSD, MO prepared the MS. All authors gave information and suggestions to improve the MS and approved the final version of the MS.

Acknowledgements

This study in Indonesia has been supported by a Grant-in-Aid (A) (21256003, 24256002) to AI and (B) (21406009, 24406011) to MO, from the Japan Society for the Promotion of Science (JSPS) and was supported by JSPS-Asia/Africa Scientific Platform Fund (2006–2011) and by the Special Coordination Fund for Promoting Science and Technology from the Ministry of Education, Japan (2003–2005, 2010–2012) to AI. We sincerely thank Christine Budke for her amendment of this MS.

Author details

¹Sari Mutiara Indonesia University, Medan, North Sumatra, Indonesia.

²Department of Parasitology, Faculty of Medicine, University of Udayana, Denpasar, Bali, Indonesia. ³Department of Veterinary Parasitology, Faculty of Veterinary Medicine, University of Udayana, Denpasar, Bali, Indonesia.

⁴Department of Health Science, Asahikawa Medical University, Asahikawa, Hokkaido, Japan. ⁵Department of Parasitology, Asahikawa Medical University, Asahikawa, Hokkaido, Japan. ⁶Section of Wildlife Diversity, Center for Human Evolution Modeling Research, Primate Research Institute, Kyoto University, Inuyama, Aichi, Japan. ⁷Laboratory of Veterinary Parasitology, Joint Faculty of Veterinary Medicine, Yamaguchi University, Yoshida, Yamaguchi, Japan.

Received: 9 December 2014 Accepted: 18 February 2015

Published online: 07 March 2015

References

1. Pawlowski Z, Schultz MG. Taeniasis and cysticercosis (*Taenia saginata*). *Adv Parasitol.* 1972;10:269–343.
2. Flisser A, Willms K, Laclette JP, Larralde C, Ridaura C, Beltran F. Cysticercosis: present state of knowledge and perspectives. New York: Academic Press; 1982. p. 1–700.
3. Gemmell M, Matyas Z, Pawlowski Z, Soulsby E. Guidelines for surveillance, prevention and control of Taeniasis/Cysticercosis. Geneva: VPH/83.49, WHO; 1983. p. 1–207.
4. Richards Jr F, Schantz PM. Cysticercosis and taeniasis. *N Engl J Med.* 1985;312:787–8.
5. Schantz PM, Moore AC, Munoz JL, Hartman BJ, Schaefer JA, Aron AM, et al. Neurocysticercosis in an Orthodox Jewish community in New York City. *N Engl J Med.* 1992;327:692–5.
6. Schantz PM, Cruz M, Sarti E, Pawlowski Z. Potential eradicability of taeniasis and cysticercosis. *Bull Pan Am Health Organ.* 1993;27:397–403.
7. White Jr AC. Neurocysticercosis: a major cause of neurological disease worldwide. *Clin Infect Dis.* 1997;24:101–13.
8. Schantz PM, Wilkins PP, Tsang VCW. Immigrants, imaging, and immunoblots: the emergence of neurocysticercosis as a significant public health problem. In: Scheld WM, Craig WA, Hughes JM, editors. *Emerging infections 2*. Washington: ASM Press; 1998. p. 213–42.
9. Craig PS, Pawlowski Z. Cestode zoonoses: echinococcosis and cysticercosis. *NATO Sci Series I: Life and Behavioural Sciences.* Amsterdam: IOS Press; 2002. p. 1–395.
10. Carpio A. Neurocysticercosis: an update. *Lancet Infect Dis.* 2002;2:751–62.
11. Schantz PM. *Taenia solium* cysticercosis: an overview of global distribution and transmission. In: Singh G, Prabhakar S, editors. *Taenia solium Cysticercosis*. From basic to clinical science. Oxon: CABI Publishing; 2002. p. 63–73.
12. Garcia HH, Gonzalez AE, Evans CAW, Gilman RH, for the Cysticercosis Working Group in Peru. *Taenia solium* cysticercosis. *Lancet.* 2003;361:547–56.
13. Ito A, Nakao M, Wandra T. Rapid Review: Human taeniasis and cysticercosis in Asia. *Lancet.* 2003;362:1918–20.
14. Murrell KD. International action planning workshop on *Taenia solium* cysticercosis/taeniasis with special focus on Eastern and Southern Africa. *Acta Trop.* 2003;87:1–191.
15. Murrell KD. WHO/FAO/OIE Guidelines for the surveillance, prevention and control of taeniasis/cysticercosis. Paris: OIE; 2005. p. 1–139.
16. Garcia HH, Del Brutto OH, for the Cysticercosis Working Group in Peru. Neurocysticercosis: updated concepts about an old disease. *Lancet Neurol.* 2005;4:653–61.

17. Ito A, Craig PS, Schantz PM. Taeniasis/cysticercosis and echinococcosis with focus on Asia and the Pacific. *Parasitol Int.* 2006;55:s1–311.
18. Ito A, Zhou XN, Craig PS, Giraudoux P. Control of cestode zoonoses in Asia: role of basic and applied science. *Parasitology.* 2013;140:1547–700.
19. Robertson LJ, van der Giessen JWB, Batz MB, Kojima M, Cahill S. Have food borne parasites finally become a global concern? *Trends Parasitol.* 2013;29:101–3.
20. Robertson LJ, Sprong H, Ortega YR, van der Giessen JWB, Fayer R. Impacts of globalisation on foodborne parasites. *Trends Parasitol.* 2014;30:37–52.
21. Torgerson PR, de Silva NR, Fevre EM, Kasuga F, Rokni MB, Zhou XN, et al. The global burden of foodborne parasitic disease: an update. *Trends Parasitol.* 2014;30:20–6.
22. Ito A, Budke CM. Culinary delights and travel? A review of zoonotic cestodiasis and metacystodiasis. *Trav Med Infect Dis.* 2014;12:582–91.
23. Dorny P, Praet N, Deckers N, Gabriel S. Emerging food-borne parasites. *Vet Parasitol.* 2009;163:196–206.
24. Willingham AL, Wu HW, Conlan J, Satrija F. Combating *Taenia solium* cysticercosis in Southeast Asia: an opportunity for improving human health and livestock production. *Adv Parasitol.* 2010;72:235–66.
25. Del Brutto OH, Rajashekhar V, White Jr AC, Tsang VC, Nash TE, Takayanagi OM, et al. Proposed diagnostic criteria for neurocysticercosis. *Neurology.* 2001;57:177–83.
26. Sorvillo FJ, Waterman SH, Richerds FO, Schantz PM. Cysticercosis surveillance: locally acquired and travel-related infections and detection of intestinal tapeworm carriers in Los Angeles County. *Am J Trop Med Hyg.* 1992;47:365–71.
27. Sorvillo FJ, DeGiorgio C, Waterman SH. Deaths from cysticercosis, United States. *Emerg Infect Dis.* 2007;13:230–5.
28. Sorvillo F, Wilkins P, Shafir S, Ebenhard M. Public health implications of cysticercosis acquired in the United States. *Emerg Infect Dis.* 2011;17:1–6.
29. Hira PR, Francis I, Abdella NA, Gupta R, Al-Ali FM, Grover S, et al. Imported and autochthonous infections in Kuwait. *Trans R Soc Trop Med Hyg.* 2004;98:233–9.
30. Leshem E, Kliens I, Bakon M, Gomori M, Karplus R, Schwartz E. Neurocysticercosis in travelers: a nation-wide study in Israel. *J Travel Med.* 2010;18:191–7.
31. Cantey PT, Coyle CM, Sorvillo FJ, Wilkins PP, Starr MC, Nash TE. Neglected parasitic infections in the United States: cysticercosis. *Am J Trop Med Hyg.* 2014;90:805–9.
32. Yanagida T, Sako Y, Nakao M, Nakaya K, Ito A. Mini Review: Taeniasis and cysticercosis due to *Taenia solium* in Japan. *Parasit Vectors.* 2012;5:18.
33. Kobayashi K, Nakamura-Uchiyama F, Nishiguchi T, Isoda K, Kokubo Y, Ando K, et al. Rare case of disseminated cysticercosis and taeniasis in a Japanese traveler after returning from India. *Am J Trop Med Hyg.* 2013;89:58–62.
34. Ito A, Putra MI, Subahar R, Sato MO, Okamoto M, Sako Y, et al. Dogs as alternative intermediate hosts of *Taenia solium* in Papua (Irian Jaya), Indonesia confirmed by highly specific ELISA and immunoblot using native and recombinant antigens and mitochondrial DNA analysis. *J Helminthol.* 2002;76:311–4.
35. Hoberg E, Alkire NL, de Queiroz A, Jones A. Out of Africa: origin of the *Taenia* tapeworms in humans. *Proc Biol Sci.* 2001;268:781–7.
36. Ito A. Basic and applied problems in developmental biology and immunobiology of cestode infections. *Parasite Immunol.* 2015;37:53–69.
37. Ito A. Nothing is perfect! Trouble-shooting in immunological and molecular studies of cestode infections. *Parasitology.* 2013;140:1551–65.
38. Simanjuntak GM, Margono SS, Okamoto M, Ito A. Taeniasis/cysticercosis in Indonesia as an emerging disease. *Parasitol Today.* 1997;13:321–3.
39. Wandra T, Margono SS, Gafar MS, Saragih JM, Sutisna P, Sudewi AAR, et al. Current situation of taeniasis/cysticercosis in Indonesia. *Trop Med Health.* 2007;35:323–8.
40. Margono SS, Ito A, Sato MO, Okamoto M, Subahar R, Yamasaki H, et al. *Taenia solium* taeniasis/cysticercosis in Papua, Indonesia in 2001: detection of human worm carriers. *J Helminthol.* 2003;77:39–42.
41. Ito A, Wandra T, Yamasaki H, Nakao M, Sako Y, Nakaya K, et al. Review article: Cysticercosis/taeniasis in Asia and the Pacific. *Vector-Borne Zoonotic Dis.* 2004;4:96–107.
42. Suroso T, Margono SS, Wandra T, Ito A. Challenges for control of taeniasis/cysticercosis in Indonesia. *Parasitol Int.* 2006;55:s161–5.
43. Wandra T, Ito A, Swastika K, Dharmawan NS, Sako Y, Okamoto M. The past and present situation of taeniasis and cysticercosis in Indonesia. *Parasitology.* 2013;140:1608–16.
44. Kosin E, Depary AAS, Djohansjah A. Taeniasis di pulau Samosir. *Maj Kedok Univ Sumatera Utara Medan.* 1972;3:5–11 (in Indonesian).
45. Fan PC, Kosman ML, Kosin E, Depary AA, Napitupulu T. Indonesia *Taenia* and taeniasis. *Yonsei Rep Trop Med.* 1990;21:33–7.
46. Wandra T, Sutisna P, Dharmawan NS, Margono SS, Sudewi R, Suroso T, et al. High prevalence of *Taenia saginata* taeniasis and status of *Taenia solium* cysticercosis in Bali, Indonesia, 2002–2004. *Trans R Soc Trop Med Hyg.* 2006;100:346–53.
47. Wandra T, Depary AA, Sutisna P, Margono SS, Suroso T, Okamoto M, et al. Taeniasis and cysticercosis in Bali and north Sumatra, Indonesia. *Parasitol Int.* 2006;55:s155–60.
48. Anantaphruti MT, Yamasaki H, Waikagul H, Wattanakulpanich D, Nuamtanong S, Maipanich W, et al. Sympatric occurrence of *Taenia asiatica*, *Taenia saginata* and *Taenia solium* in Kanchanaburi Province, western Thailand. *Emerg Infect Dis.* 2007;13:1413–6.
49. Li T, Craig PS, Ito A, Chen X, Qiu D, Qiu J, et al. Taeniasis/cysticercosis in a Tibetan population in Sichuan Province, China. *Acta Trop.* 2006;100:223–31.
50. Okamoto M, Nakao M, Blair D, Anantaphruti MT, Waikagul J, Ito A. Evidence of hybridization between *Taenia saginata* and *Taenia asiatica*. *Parasitol Int.* 2010;59:70–4.
51. Yamane K, Suzuki Y, Tachi E, Li TY, Chen XW, Nakao M, et al. Recent hybridization between *Taenia asiatica* and *Taenia saginata*. *Parasitol Int.* 2012;61:351–5.
52. Yamane K, Yanagida T, Li T, Chen X, Dekumyoin P, Waikagul J, et al. Complicated relationships between *Taenia saginata* and *Taenia asiatica* and their hybrids. *Parasitology.* 2013;140:1595–601.
53. Tumada LR, Margono SS. Cysticercosis in the area of the Wissel Lakes, West Irian. *Southeast Asian J Trop Med Public Health.* 1973;4:371–6.
54. Desowitz RS, Margono SS, Sutjahyo, Simanjuntak G. Observations on the application of counterimmunoelectrophoresis for the seroepidemiology of human cysticercosis. *Southeast Asian J Trop Med Public Health.* 1977;8:303–7.
55. Subianto DB, Tumada LR, Margono SS. Burns and epileptic fits associated with cysticercosis in mountain people of Irian Jaya. *Trop Geogr Med.* 1978;30:275–8.
56. Coker-Vann MR, Subianto DB, Brown P, Diwan AR, Desowitz R, Garruto RM, et al. ELISA antibodies to cysticerci of *Taenia solium* in human populations in new Guinea, Oceania and Southeast Asia. *Southeast Asian J Trop Med Public Health.* 1981;12:499–505.
57. Handali S, Liying H, Lusikoy C, Senis J, Sihombing D. A survey report—July 1993: Cysticercosis in the Grand Dali valley, Jayawijaya district, Irian Jaya province, Indonesia. *Southeast Asian J Trop Med Public Health.* 1997;28:22–5.
58. Wandra T, Subahar R, Simanjuntak GM, Margono SS, Suroso T, Okamoto M, et al. Resurgence of cases of epileptic seizures and burns associated with cysticercosis in Assologaima, Jayawijaya, Irian Jaya, Indonesia, 1991–95. *Trans R Soc Trop Med Hyg.* 2000;94:46–50.
59. Margono SS, Ito A, Suroso T. The problem of taeniasis and cysticercosis in Irian Jaya, Indonesia. *Med J Indonesia.* 2001;10:110–4.
60. Margono SS, Subahar R, Hamid A, Wandra T, Sudewi SS, Sutisna P, et al. Cysticercosis in Indonesia: epidemiological aspects. *Southeast Asian J Trop Med Public Health.* 2001;32 Suppl 2:79–84.
61. Subahar R, Hamid A, Purba W, Wandra T, Karma C, Sako Y, et al. *Taenia solium* infection in Irian Jaya (West Papua), Indonesia: a pilot serological survey of human and porcine cysticercosis in Jayawijaya District. *Trans R Soc Trop Med Hyg.* 2001;95:388–90.
62. Margono SS, Ito A, Suroso T. The problem of taeniasis and cysticercosis in Irian Jaya (Papua), Indonesia. In: Chen ER, Yamaguchi T, Chung WC, editors. *Parasitic Zoonoses in Asian-Pacific Regions 2000*. Taipei: The Organizing Committee Asian-Pacific Congress for Parasitic Zoonoses Taipei; 2000. p. 55–64.
63. Wandra T, Ito A, Yamasaki H, Suroso T, Margono SS. *Taenia solium* in Irian Jaya, Indonesia. *Emerg Infect Dis.* 2003;9:884–5.
64. Simanjuntak GM, Widarso HS. The current *Taenia solium* taeniasis/cysticercosis situation in Indonesia. *Southeast Asian J Trop Med Public Health.* 2004;35 Suppl 1:240–6.
65. Margono SS, Wandra T, Swarsono MF, Murni S, Craig PS, Ito A. Taeniasis/cysticercosis in Papua (Irian Jaya), Indonesia. *Parasitol Int.* 2006;55:s143–8.
66. Salim L, Ang A, Handali S, Cysticercosis Working Group in Papua, Tsang VC. Seroepidemiologic survey of cysticercosis-taeniasis in four central highland districts of Papua, Indonesia. *Am J Trop Med Hyg.* 2009;80:384–8.
67. Sako Y, Itoh S, Okamoto M, Nakaya K, Ito A. Simple and reliable preparation of immunodiagnostic antigens for *Taenia solium* cysticercosis. *Parasitology.* 2013;140:1589–94.

68. Wandra T, Margono SS, Suroso T, Wibisono H, Ito A. Taeniasis/cysticercosis in Indonesia. *Southeast Asian J Trop Med Public Health*. 2007;38 Suppl 1:140–3.
69. Ito A, Plancarte A, Ma L, Kong Y, Flisser A, Cho YS, et al. Novel antigens for neurocysticercosis: simple method for preparation and evaluation for serodiagnosis. *Am J Trop Med Hyg*. 1998;59:291–4.
70. Ito A, Plancarte A, Nakao M, Nakaya K, Ikejima T, Piao ZX, et al. ELISA and immunoblot using purified glycoproteins for serodiagnosis of cysticercosis in pigs naturally infected with *Taenia solium*. *J Helminthol*. 1999;73:363–5.
71. Sako Y, Nakao M, Ikejima T, Piao XZ, Nakaya K, Ito A. Molecular characterization and diagnostic value of *Taenia solium* low-molecular-weight antigen genes. *J Clin Microbiol*. 2000;38:4439–44.
72. Ito A, Nakao M, Sako Y, Nakaya K. Neurocysticercosis and echinococcosis in Asia: Recent advances in the establishment of highly reliable differential serodiagnosis for international collaboration. *Southeast Asian J Trop Med Public Health*. 2000;31 Suppl 1:16–20.
73. Ito A, Wandra T, Subahar R, Hamid A, Yamasaki H, Sako Y, et al. Recent advances in basic and applied science for the control of taeniasis/cysticercosis in Asia. *Southeast Asian J Trop Med Public Health*. 2002;33 Suppl 3:79–82.
74. Sato MO, Yamasaki H, Sako Y, Nakao M, Nakaya K, Plancarte A, et al. Evaluation of tongue inspection and serology for diagnosis of *Taenia solium* cysticercosis in swine: usefulness of ELISA using purified glycoproteins and recombinant antigen. *Vet Parasitol*. 2003;111:309–22.
75. Sato MO, Sako Y, Nakao M, Yamasaki H, Nakaya K, Ito A. Evaluation of purified *Taenia solium* glycoprotein and recombinant antigens in the serologic detection of human and swine cysticercosis. *J Infect Dis*. 2006;194:1783–90.
76. Ito A, Takayanagi MO, Sako Y, Sato MO, Odashima NS, Yamasaki H, et al. Review: Neurocysticercosis: the usefulness of highly specific serology and molecular confirmation of histopathologic specimens. *Southeast Asian J Trop Med Public Health*. 2006;37 Suppl 3:74–81.
77. Sato MO, Sako Y, Nakao M, Wandra T, Yamasaki H, Nakaya K, et al. Usefulness of immunological and molecular tools: programs towards control and eradication of cysticercosis in endemic areas. *Southeast Asian J Trop Med Public Health*. 2007;38 Suppl 1:159–65.
78. Ito A, Sako Y, Nakao M, Nakaya K, Okamoto M, Wandra T, et al. Molecular and immunological diagnosis of taeniasis and cysticercosis in Asia and the Pacific. *Southeast Asian J Trop Med Public Health*. 2008;39 Suppl 1:37–47.
79. Ngoerah IGNG. Cysticercosis of the central nervous system. *Maj Ilmiah Univ Ud*. 1975;2:31–8. In Indonesian.
80. Sutisna P. Parasitic infections in humans in Bali: a review. *Bull Penelitian Kesehatan*. 1989;17:276–83.
81. Sutisna P. The problem of taeniasis in Banjar Kelod, Renon, Denpasar. *Medika*. 1990;7:543–9.
82. Sutisna P. Sistiserkosis di Bali: laporan 6 kasus. *Maj Ilmiah Univ Ud*. 1994;41:5–9 (in Indonesian).
83. Suweta IG. The situation of cysticercosis/taeniasis in animal/man in Bali. *Southeast Asian J Trop Med Public Health*. 1991;22(Suppl):236–8.
84. Dharmawan NS, Siregar EAA, He S, Hsibuan KM. Cysticercosis padababi di Bali. *Hemera Zoa*. 1992;75:25–37 (in Indonesian).
85. Theis JH, Goldsmith RS, Flisser A, Koss J, Chionino C, Plancarte A, et al. Detection by immunoblot assay of antibodies to *Taenia solium* cysticercosis in sera from residents of rural communities and from epileptic patients in Bali, Indonesia. *Southeast Asian J Trop Med Public Health*. 1994;25:464–8.
86. Sutisna P, Kapti IN, Allan JC, Rodrigues-Canul R, Craig PS. Prevalence of taeniasis and cysticercosis in Banjar Pamesan, Ketewel village, Gianyar, Bali. *Maj Kedok Ud*. 2000;31:226–34.
87. Margono SS, Himawan S, Purnama TA, Subahar R, Hamid A, Ito A. Multiple cysticercus nodules in skin and brain in a Balinese woman: a case report. *Med J Indonesia*. 2002;11:169–73.
88. Sudewi AAR, Wandra T, Artha A, Nkouawa A, Ito A. *Taenia solium* cysticercosis, Bali, Indonesia, with serology and mitochondrial DNA. *Trans R Soc Trop Med Hyg*. 2008;102:96–8.
89. Wandra T, Sudewi RAA, Swastika IK, Sutisna P, Dharmawan NS, Yulfi H, et al. Taeniasis/cysticercosis in Bali, Indonesia. *Southeast Asian J Trop Med Public Health*. 2011;42:793–802.
90. Swastika K, Dewiyani CI, Yanagida T, Sako Y, Sudamaja M, Sutisna P, et al. An ocular cysticercosis in Bali, Indonesia caused by *Taenia solium* Asian genotype. *Parasitol Int*. 2012;61:378–80.
91. Raka Sudewi AA, Nuartha AABN. Gambaran CT scan beberapa kasus neurosistiserkosis di Rumah Sakit Umum Pusat Denpasar. Conference and Yearly Scientific Meeting, Indonesian Neurologist Association, Malang, Indonesia, 1998 (in Indonesian).
92. Sarti E, Schantz PM, Avila G, Ambrosio J, Medina-Santilan R, Flisser A. Mass treatment against human taeniasis for the control of cysticercosis: a population-based intervention study. *Trans R Soc Trop Med Hyg*. 2000;94:85–9.
93. Ito A, Okamoto M, Li T, Wandra T, Dharmawan NS, Swastika KI, et al. The first workshop on towards the control of cestode zoonoses in Asia and Africa. *Parasite Vectors*. 2011;4:114.
94. Sarti E, Schantz PM, Plancarte A, Wilson M, Gutierrez IO, Lopez AS, et al. Prevalence and risk factors for *Taenia solium* taeniasis and cysticercosis in humans and pigs in a village in Morelos, Mexico. *Am J Trop Med Hyg*. 1992;46:677–85.
95. Sarti E, Schantz PM, Plancarte A, Wilson M, Gutierrez OI, Aguilera J, et al. Epidemiological investigation of *Taenia solium* taeniasis and cysticercosis in a rural village of Michoacan state, Mexico. *Trans R Soc Trop Med Hyg*. 1994;88:49–52.
96. Gilman RH, Gonzalez AE, Llanos-Zavalaga FL, Tsang VCV, Garcia HH, for the Cysticercosis Working Group in Peru. Prevention and control of *Taenia solium* taeniasis/cysticercosis in Peru. *Pathog Glob Health*. 2012;106:312–8.
97. Yamasaki H, Matsunaga S, Yamamura K, Chang CC, Kawamura S, Sako Y, et al. Solitary neurocysticercosis caused by Asian genotype of *Taenia solium* confirmed by mitochondrial DNA analysis. *J Clin Microbiol*. 2004;42:3891–3.
98. Yamasaki H, Nakao M, Sako Y, Nakaya K, Ito A. Molecular identification of *Taenia solium* cysticercus genotype in the histopathological specimens. *Southeast Asian J Trop Med Public Health*. 2005;36 Suppl 4:131–4.
99. Ito A, Yamasaki H, Nakao M, Sako Y, Nakaya K, Mamuti W, et al. Review: Echinococcosis and cysticercosis in Asia: evaluation of the modern technology for epidemiological study. *Southeast Asian J Trop Med Public Health*. 2003;34 Suppl 2:103–7.
100. Yamasaki H, Allan JC, Sato MO, Nakao M, Sako Y, Nakaya K, et al. DNA differential diagnosis of taeniasis/cysticercosis by multiplex PCR. *J Clin Microbiol*. 2004;42:548–53.
101. Hüttner M, Nakao M, Wassermann T, Siefert L, Boomker JDF, Dinkel A, et al. Genetic characterization and phylogenetic position of *Echinococcus felidis* (Cestoda: Taeniidae) from the African lion. *Int J Parasitol*. 2008;38:861–8.
102. Nkouawa A, Sako Y, Nakao M, Nakaya K, Ito A. Loop-mediated isothermal amplification method for differentiation and rapid detection of *Taenia* species. *J Clin Microbiol*. 2009;47:168–74.
103. Nkouawa A, Sako Y, Li T, Chen X, Wandra T, Swastika K, et al. Evaluation of loop-mediated isothermal amplification method using fecal specimens for differential detection of *Taenia* species. *J Clin Microbiol*. 2010;48:3350–2.
104. Nkouawa A, Sako Y, Li T, Chen X, Nakao M, Yanagida T, et al. Loop-mediated isothermal amplification method for a differential identification of *Taenia* tapeworms from human: application to a field survey. *Parasitol Int*. 2012;61:723–5.
105. Yanagida T, Yuzawa I, Joshi DD, Sako Y, Nakao M, Nakaya K, et al. Neurocysticercosis: assessing where the infection was acquired? *J Travel Med*. 2010;17:206–8.
106. Jongwitiwes U, Yanagida T, Ito A, Kline S. Isolated intradural-extramedullary spinal cysticercosis: a case report. *J Travel Med*. 2011;18:284–7.
107. Sako Y, Ito A. Recent advances in serodiagnosis for cysticercosis. *Southeast Asian J Trop Med Public Health*. 2001;32 Suppl 2:98–104.
108. Sako Y, Nakao M, Nakaya K, Yamasaki H, Ito A. Recombinant antigens for serodiagnosis of cysticercosis and echinococcosis. *Parasitol Int*. 2006;55:69–73.
109. Ito A, Li TY, Chen XW, Long CP, Yanagida T, Nakao M, et al. Mini review on chemotherapy of taeniasis and cysticercosis due to *Taenia solium* in Asia, and a case report with 20 tapeworms. *Trop Biomed*. 2013;30:164–73.
110. Ito A, Okamoto M, Wandra T, Wibisono H, Anaphruti MT, Waikagul J, et al. Review: Taeniasis and cysticercosis in Asia and the Pacific: present state of knowledge and perspectives. *Southeast Asian J Trop Med Public Health*. 2005;36 Suppl 4:123–30.
111. Ito A, Wandra T, Sato MO, Mamuti W, Xiao N, Sako Y, et al. Review: Towards the international collaboration for detection, surveillance and control of taeniasis/cysticercosis and echinococcosis in Asia and the Pacific. *Southeast Asian J Trop Med Public Health*. 2006;37 Suppl 3:82–90.
112. Ito A, Okamoto M, Wandra T, Wibisono H, Anaphruti MT, Waikagul J, et al. Review: The present situation of taeniasis and cysticercosis in Asia and the Pacific. *Southeast Asian J Trop Med Public Health*. 2007;38 Suppl 1:119–24.

113. Johnson KS, Harrison GB, Lightowlers MW, O'Hoy KL, Cogle WG, Dempster RP, et al. Vaccination against ovine cysticercosis using a defined recombinant antigen. *Nature*. 1989;338:585–7.
114. Lightowlers MW. Eradication of *Taenia solium* cysticercosis: a role for vaccination of pigs. *Int J Parasitol*. 2010;40:1183–92.
115. Jayashi CM, Gonzalez AE, Neyra RC, Kyngdon CT, Gauci CG, Lightowlers MW. Characterisation of antibody responses in pigs induced by recombinant oncosphere antigens from *Taenia solium*. *Vaccine*. 2012;30:7475–80.
116. Lightowlers MW. Control of *Taenia solium* taeniasis/cysticercosis: past practices and new possibilities. *Parasitology*. 2013;140:1566–77.
117. Gonzalez AE, Gauci CG, Barber D, Gilman RH, Tsang VC, Garcia HH, et al. Vaccination of pigs to control human neurocysticercosis. *Am J Trop Med Hyg*. 2005;72:837–9.

**Submit your next manuscript to BioMed Central
and take full advantage of:**

- Convenient online submission
- Thorough peer review
- No space constraints or color figure charges
- Immediate publication on acceptance
- Inclusion in PubMed, CAS, Scopus and Google Scholar
- Research which is freely available for redistribution

Submit your manuscript at
www.biomedcentral.com/submit

