

# AMCoR

Asahikawa Medical College Repository <http://amcor.asahikawa-med.ac.jp/>

The Journal of ophthalmic photography (2002) 24(1):36-39.

The Usefulness of Fundus Photography with Red Light for the Diagnosis of Central Serous Chorioretinopathy

Katsuhiko, Fukui ; Akitoshi, Yoshida ; Yuji, Kato ; Hiromasa, Igarashi

## ORIGINAL ARTICLE



Katsuhiko Fukui, MT  
Akitoshi Yoshida, MD, PhD

Department of Ophthalmology  
Asahikawa Medical College  
2-1-1-1 Midorigaoka-Higashi  
Asahikawa, 078-8510, Japan  
+81/166-65-2543  
+81/166-65-2549 Fax  
kfukui@asahikawa-med.ac.jp

Yuji Kato, MD, PhD  
Hiromasa Igarashi, MD, PhD

Kushiro Red Cross Hospital  
21-14 Shineimachi  
Kushiro, 078-0032, Japan

## The Usefulness of Fundus Photography with Red Light for the Diagnosis of Central Serous Chorioretinopathy

### Abstract

*Fundus photography using monochromatic red light is a well-known procedure. However, it is used infrequently because of the difficulty with interpretation. The authors studied the usefulness of red light fundus photography for the diagnosis of central serous chorioretinopathy (CSCR) using a Canon 60Z wide-angle fundus camera and a 23A Wratten Gelatin Filter. This method gave additional information from typical CSCR lesions compared to color photography. Our results suggest that fundus photography with red light is a simple and useful examination for CSCR and that it should be used in conjunction with color photography and fluorescein angiography.*

### KEY WORDS

fundus photography, red light, red filter, central serous chorioretinopathy, monochromatic fundus photography, Wratten Gelatin Filter-No23A

### INTRODUCTION

Color fundus photography and fundus fluorescein angiography (FFA) are established techniques for the routine examination for retinal pathology. Subretinal diseases such as age-related disciform macular degeneration requires detailed information of the choroid and retinal pigment epithelium (RPE), which cannot easily be obtained by conventional imaging techniques.<sup>1-7</sup> A variety of clinical or experimental methods have been developed for examining choroidal lesions. Indocyanine green angiography has recently been in the spotlight. Although

retinal and choroidal hemodynamics can be photographed using infrared light by this method, interpretation of the angiograms is not standardized, which prevents widespread use of the method. Although the principles of red light retinal imaging have been known for some time, little attention has been paid to it because of the difficulty in interpretation of the images.<sup>8,9</sup> The authors studied the usefulness and limitations of red light fundus photography by reviewing some cases of central serous chorioretinopathy.<sup>9</sup>

### METHODS

A Canon 60Z wide-angle fundus camera (Canon, Tokyo, Japan) was used to photograph the fundus using a Wratten Gelatin Filter No23A, (Eastman Kodak, Rochester N.Y, U.S.A.), 560-900 nanometers transmission. Standard methods were used for color fundus photography and FFA (Table 1). All red light images were obtained before fluorescein injection.

### RESULTS

**Case 1: typical CSCR.** Color fundus photography showed a serous retinal detachment from the fovea to the temporal area (Figure 1a). FFA showed pooling of fluorescein in the same area (Figure 1b). Red light fundus

Table 1: Film and Flash Intensities

	Film	Flash Intensity
Color Fundus Photography	Kodachrome64	CanonCF60-Z 150ws
FFA	Tri-Xpan	CanonCF60-Z 300ws
Red Light Photography*	Tri-Xpan	CanonCF60-Z 50ws

\*Wratten Gelatin Filter-No23A  
Developer D-76

photography also revealed a serous retinal detachment (Figure 1c).

**Case2: typical CSCR.** Color fundus photography showed a less obvious border between the lesion and normal tissues in comparison with Case 1 (Figure 2a). However, multiple leaks of fluorescein with a serous retinal detachment were easily observed with both FFA (Figure 2b) and red light photography (Figure 2c).

**Case3: CSCR during treatment.** Visual acuity returned to a normal range after the initial episode of CSCR whilst severe metamorphopsia remained unchanged. Serous retinal detachment was observed with difficulty from the color fundus photographs, which provides the impression of CSCR resolution (Figure 3a). However, FFA showed obvious leakage of fluorescein from the retinal pigment epithelium forming a serous

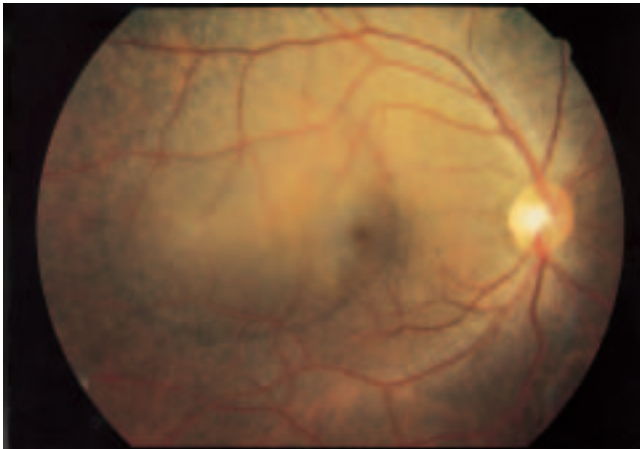


Figure 1a: Case 1 typical CSCR (Color fundus photography).

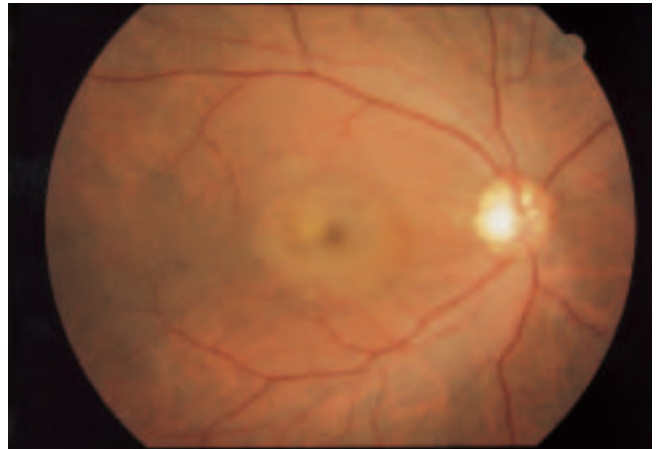

Figure 2a: Case 2 typical CSCR (Color fundus photography).

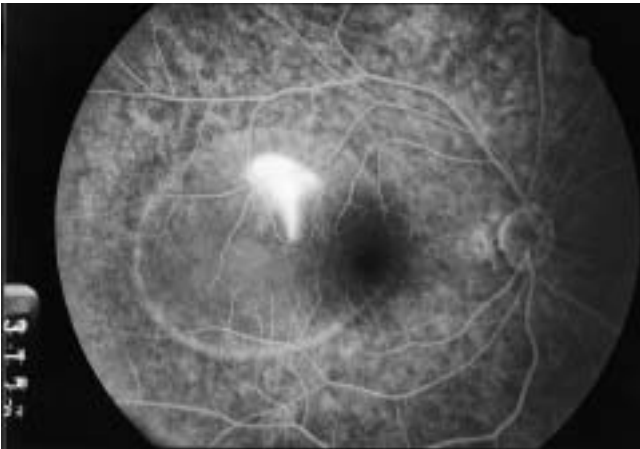

Figure 1b: Case 1 typical CSCR (FFA).

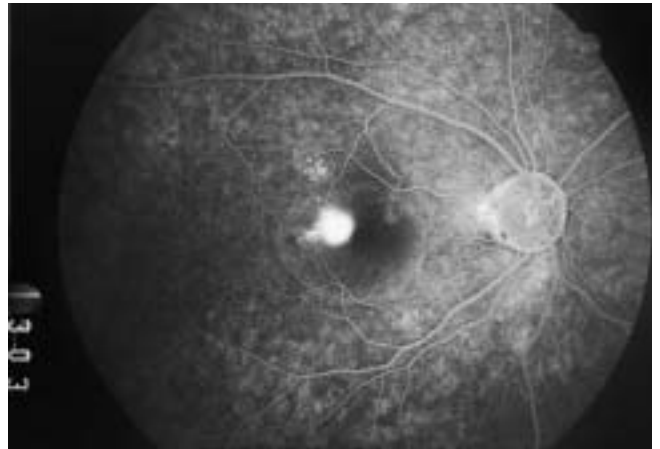


Figure 2b: Case 2 typical CSCR (FFA).

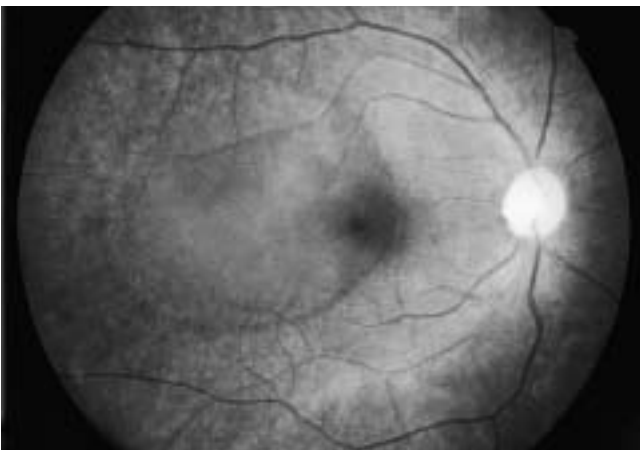


Figure 1c: Case1 typical CSCR (Red filter).

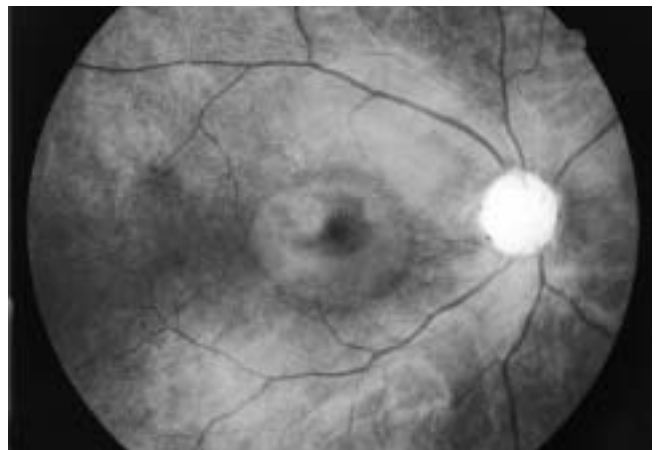


Figure 2c: Case 2 typical CSCR (Red filter).

detachment (Figure 3b). Red light fundus photography revealed a lesion around the fovea with a serous detachment of two disc-diameters (Figure 3c).

**Case 4: chronic recurrent CSCR.** This patient alternated between recurrence and remission on several occasions. Visual acuity was satisfactory whilst an Amsler chart revealed severe metamorphopsia. Color fundus photography showed no obvious serous retinal detach-

ment but a large lesion around the fovea (Figure 4a). FFA showed multiple, punctuate, mild leakage of fluorescein, but fluorescein pooling in a serous detachment was not observed (Figure 4b). Red light fundus photography revealed that the lesion around the fovea was obviously larger than that seen on the color fundus photographs (Figure 4a).

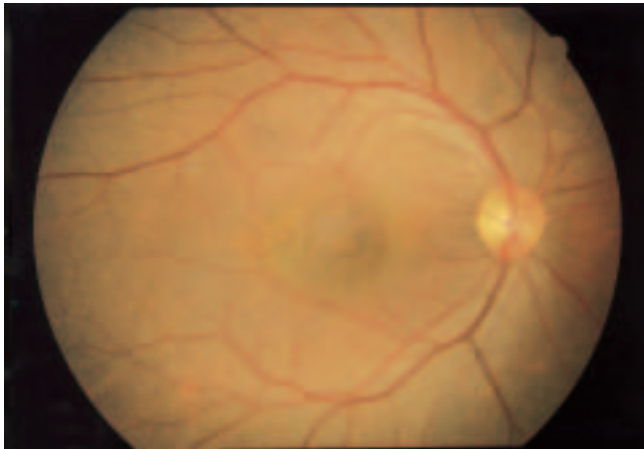

Figure 3a: Case 3 CSCR during treatment (Color fundus photography).

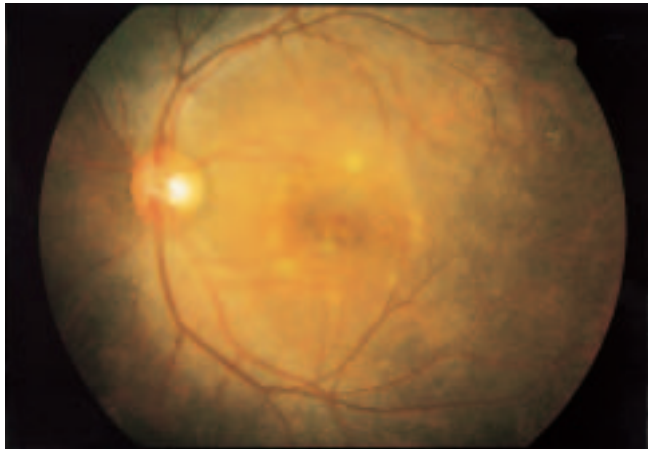


Figure 4a: Case 4 chronic recurrent CSCR (Color fundus photography).

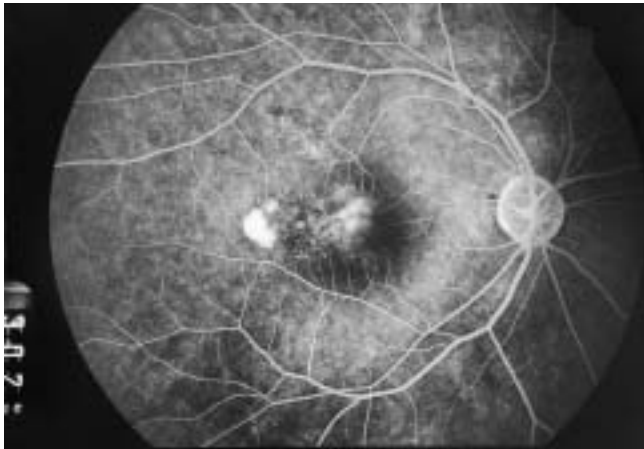


Figure 3b: Case 3 CSCR during treatment (FFA).

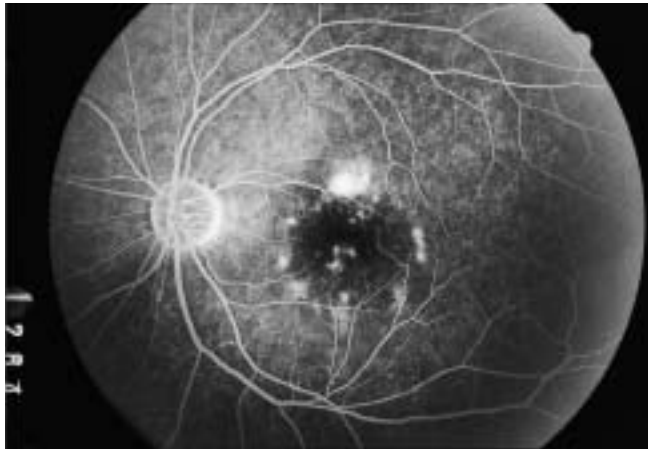


Figure 4b: Case 4 chronic recurrent CSCR (FFA).

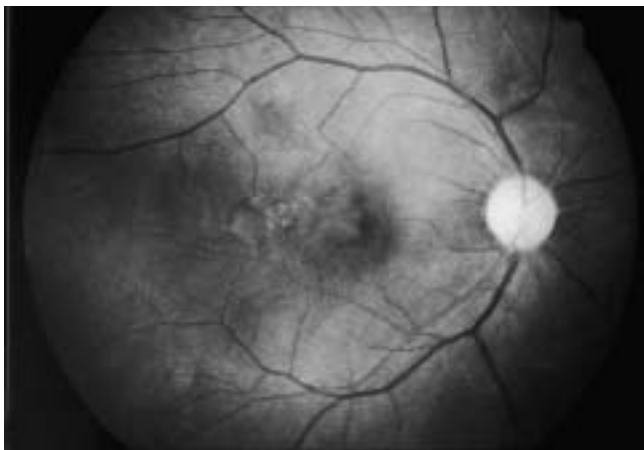


Figure 3c: Case 3 CSCR during treatment (Red filter).

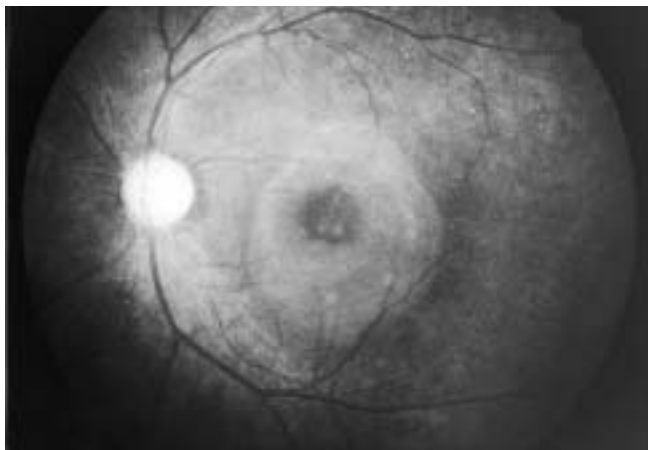


Figure 4c: Case 4 chronic recurrent CSCR (Red filter).

## DISCUSSION

Central serous chorioretinopathy is a process forming sensory retinal detachment, with or without RPE detachment, around the macula due to infiltration of serous components from the choriocapillaris into the subretinal space resulting from RPE dysfunction. This disease frequently occurs in young males and recurs in at least 50% of patients. Thus, careful follow-up is important over lengthy periods. However, a typical CSCR case showing obvious serous detachment is relatively rare in our community. In most chronic cases, FFA only reveals punctuate enhancement of fluorescein in the RPE although patients complain of obvious metamorphopsia or impairment of visual acuity.

This limited study demonstrated that a typical CSCR lesion could be observed using a red filter that was less visible with both color photography and FFA. In addition, this method does not require the use of any contrast medium and reduces the physical and economic burden on patients. Since this method can be performed as easily as fundus photography, it is a useful means for long term follow-up of CSCR patients as well as an excellent routine screening test for fundus diseases. Red light fundus photography is not a new method, however, it has been previously shown that this method may be useful for documenting other subretinal lesions. However, a subretinal lesion is often obscured by retinal scarring, for example disciform ARMD. Therefore, red light fundus photography was not considered satisfactory for assisting with the diagnosis of ARMD.

## CONCLUSION

This study revealed that red light fundus photography is a simple and useful examination method for the observation of CSCR lesions and follow-up of CSCR patients. Red light fundus photography should be used as one of the examination tools for CSCR.

## REFERENCES

1. Kugelberg, I. Der Augenhintergrund iminfrarotem Licht. *Acta Ophthalmol.* 12:179,1934.
2. Poss, A.M.: Monochromatic Ophthalmoscopy. *Tr. Am. Ophthalmol. Soc.*, 63:276-293,1965.
3. Behrendt, T. and Wilson, L.A.: Spectral reflectance photography of the retina, *Am. J. Ophthalmol.* 59:1079-1088,1965.
4. Behrendt, T. and Duane, T.D.: Investigation of fundus oculi with spectral reflectance photography, I. Depth and integrity of fundus structures, *Arch. Ophthalmol.* 75:375-379,1966.
5. Delori, F.C. and Gragoudas, E.S.: Examination of the ocular fundus with monochromatic light, *Ann. Ophthalmol.* 8:703-709,1976.
6. Delori, F.C., and Gragoudas, E.S., Francisco, R. and Pruett, R.C.: Monochromatic ophthalmoscopy and fundus photography, The normal fundus, *Arch. Ophthalmol.* 95:861-868,1977.
7. Ducrey, N.M., Delori, F.C. and Gragoudas, E.S.: Monochromatic ophthalmoscopy and fundus photography, II. The pathological fundus, *Arch. Ophthalmol.* 97:288-293,1979.
8. Brad C. Clifton: Monochromatic Imaging of Choroidal Tumors, *Journal of Ophthalmic Photography* Vol. 17. No.1 , 32-35,1995.
9. Katsuhiko Fukui, Yuji Kato, Hiromasa Igarashi: Screening of Choroidal Disease Using Fundus Photography with Red Rays, *The Japanese Journal of Medical Photography* Vol.37. No1. 2-11,1999.