

AMCoR

Asahikawa Medical University Repository <http://amcor.asahikawa-med.ac.jp/>

The Journal of bone and joint surgery. American volume (2011.Jun) 93
卷11号:e60.

Recurrent posterior dislocation of the hip treated with periacetabular
osteotomy: a case report

Yamanaka Yasuhiro, Ito Hiroshi, Hirayama Teruhisa, Tanino
Hiromasa, Sato Tatsuya, Matsuno Takeo

Recurrent Posterior Dislocation of the Hip Treated with Periacetabular Osteotomy

A Case Report

Yasuhiro Yamanaka, MD, Hiroshi Ito, MD, Teruhisa Hirayama, MD,
Hiromasa Tanino, MD, Tatsuya Sato, MD, and Takeo Matsuno, MD

Investigation performed at the Department of Orthopaedic Surgery, Asahikawa Medical College, Asahikawa, Japan

Recurrent traumatic dislocation of the hip is rarely observed. We present the case of a patient who had traumatic hip dislocation associated with a dysplastic acetabulum and recurrent instability who was managed with capsular repair and periacetabular osteotomy to enhance the stability of the joint. At the time of the latest follow-up, the patient had an excellent clinical result and returned to his occupation as a skiing instructor. This case report was approved by our institutional review board. The patient was informed that data concerning this case would be submitted for publication.

Case Report

In April 2005, a twenty-year-old man with no previous hip problems fell down while snowboarding and sustained a posterior dislocation of the left hip. At a nearby hospital, radiographs of the pelvis showed a posterior dislocation of the hip joint without fracture (an Epstein-Thompson type-I dislocation¹) (Figs. 1-A and 1-B). The patient was immediately taken to the operating room for a closed reduction of the left hip under general anesthesia. Postoperatively, he was placed in skin traction for one week. After three weeks, he was allowed to walk with crutches and was discharged from the hospital. After six weeks, he returned to full weight-bearing and progressed gradually to activities as tolerated. Three months after the first injury, he had a second dislocation of the same hip when he fell down while skateboarding (see Appendix). He was taken to the hospital and was managed with the same protocol of closed reduction and progressive weight-bearing. After the second injury, the patient had no other episodes of dislocation for two years. In August 2007, while he was playing baseball, he pivoted on the left leg and dislocated the left hip for the third time. He was taken to a nearby hospital and was managed with closed reduction

under sedation. He was then referred to our orthopaedic service for definitive treatment of recurrent dislocation of the hip.

Physical examination revealed a healthy-appearing twenty-three-year-old man who was 168 cm tall and weighed 62 kg. He experienced an apprehension of dislocation with flexion and internal rotation of the left hip. Radiographs and a computed tomography (CT) scan revealed a mildly dysplastic acetabulum. The center-edge angle of the right hip was 15°, the center-edge angle of the left hip was 17°, the acetabular index of the right hip was 15°, and the acetabular index of the left hip was 14°. There was mild retroversion of the left acetabulum as indicated by a small positive cross-over sign (Figs. 2-A and 2-B). Magnetic resonance imaging (MRI) suggested a torn labrum and posterior capsule (Fig. 3). The Harris hip score was 85 points.

In October 2007, the left hip was treated operatively. First, a modified periacetabular osteotomy was performed through an Ollier lateral U approach² along with a trochanteric osteotomy. The greater trochanter with its tendinous insertion was retracted proximally to expose the entire joint capsule. The short external rotators appeared to be scarred and the posterior capsule was torn, but the acetabular labrum was intact on visual inspection and probing. The pelvic osteotomy was performed with a curved osteotome and extended circumferentially around the acetabulum. The posterior column was preserved. For patients with anterolateral acetabular deficiency, corrective repositioning (external rotation and adduction) of the osteotomized fragment should be performed to improve anterior and lateral coverage. In this case, however, corrective repositioning of internal rotation and adduction was added to improve posterior and lateral coverage (see Appendix). Four bioabsorbable cortical screws were inserted to fix the acetabular fragment. A bone graft was not used.

Disclosure: The authors did not receive any outside funding or grants in support of their research for or preparation of this work. Neither they nor a member of their immediate families received payments or other benefits or a commitment or agreement to provide such benefits from a commercial entity.

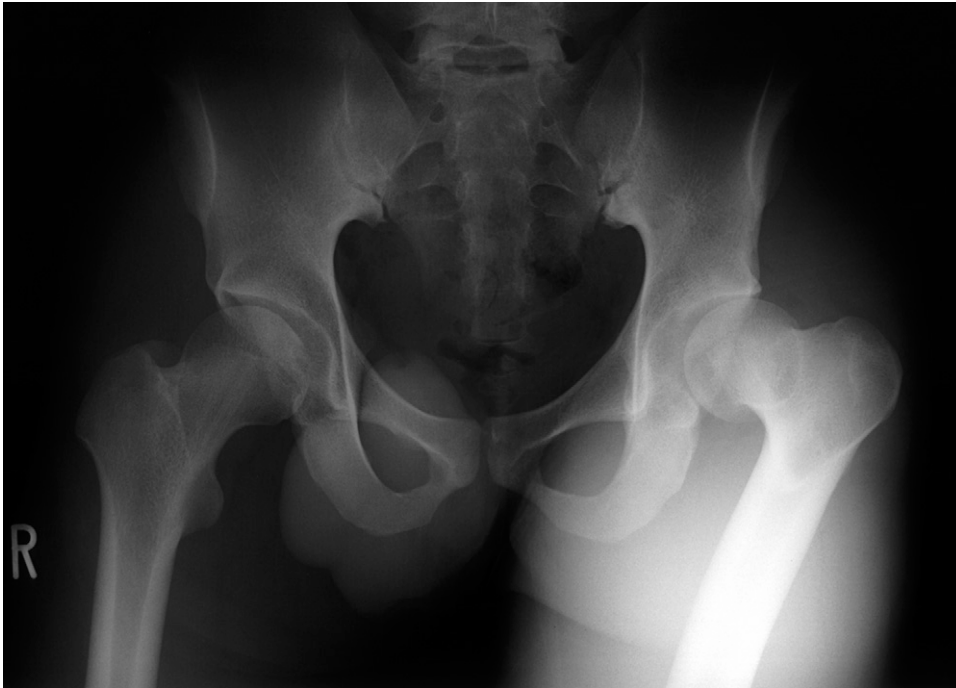


Fig. 1-A

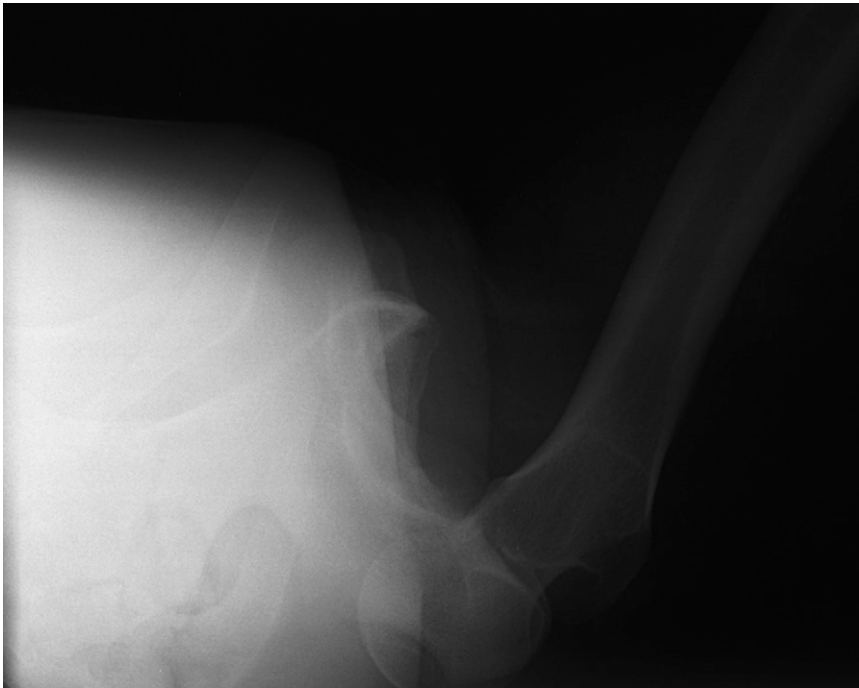


Fig. 1-B

Anteroposterior (Fig. 1-A) and frog-leg lateral (Fig. 1-B) radiographs showing the first dislocation of the left hip.

The retracted capsule was mobilized superiorly to permit direct closure. The reconstruction was completed with a repair of the torn posterior capsule with four interrupted sutures of no.-1 braided nonabsorbable material (see Appendix), and the greater trochanter was reduced and fixed with two 6.5-mm metallic cancellous screws. The center-edge angle of the left hip

increased from 17° to 28° , and the acetabular index decreased from 14° to 2° .

Postoperatively, the patient avoided excessive flexion, adduction, and internal rotation of the left hip for four weeks. He was allowed to walk with crutches after one week. After eight weeks, he started to walk with full weight-bearing. At four

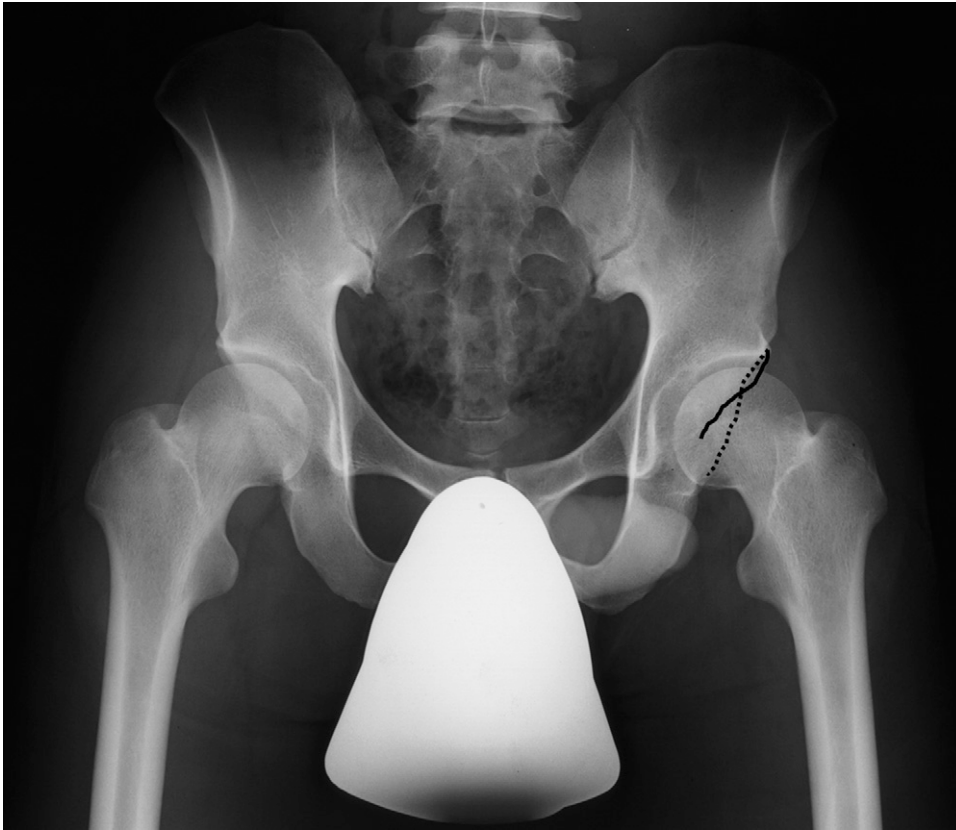


Fig. 2-A

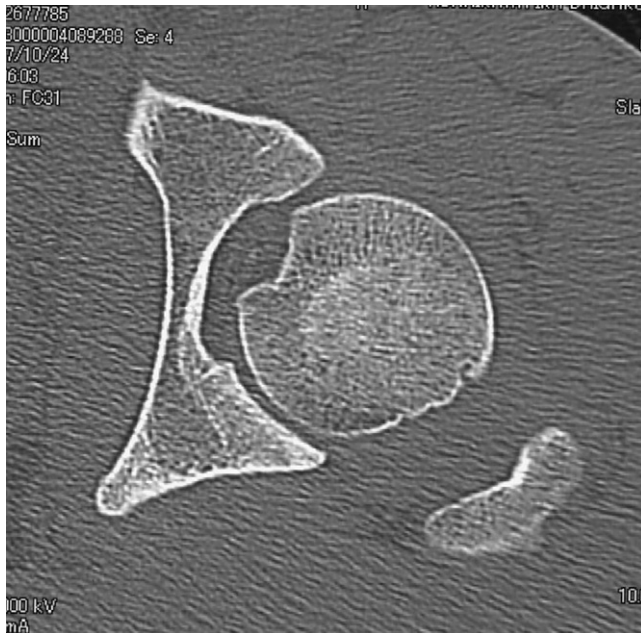

Fig. 2-B

Anteroposterior radiograph (Fig. 2-A) and CT scan (Fig. 2-B) of the pelvis, demonstrating a mildly dysplastic acetabulum without fractures. Mild retroversion of the acetabulum as indicated by a small positive cross-over sign is drawn on the anteroposterior radiograph (Fig. 2-A). The solid line indicates the anterior aspect of the acetabulum, and the dotted line indicates the posterior aspect of the acetabulum.

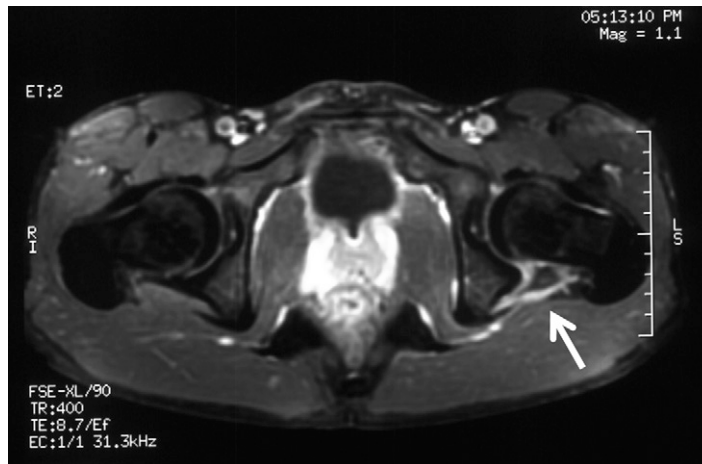


Fig. 3
Axial T2-weighted magnetic resonance image with fat suppression, showing the torn posterior capsule of the left hip (arrow).

months, he returned to full activity, including downhill skiing. In November 2008, one year after the operation, the internal fixation screws were removed from the greater trochanter. The patient returned to work as a skiing and snowboarding in-

structor. Two years and six months after the acetabular osteotomy, the patient had an excellent clinical result. He was working as a skiing and snowboarding instructor without any difficulty. The latest Harris hip score was 96 points (Fig. 4).

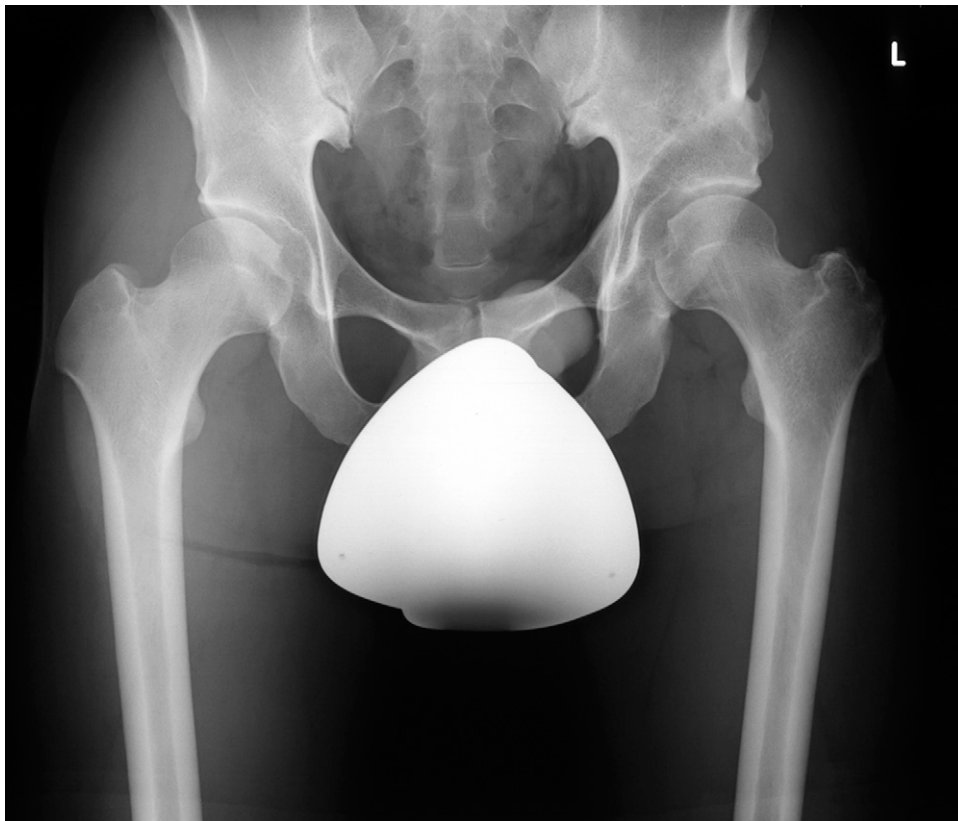

Fig. 4
Anteroposterior pelvic radiograph, made at the time of the latest follow-up, demonstrating anteversion of the acetabulum, an increased lateral center-edge angle, a decreased acetabular index, and a negative cross-over sign.

Discussion

Recurrent dislocation of the adult hip is rarely reported. In this setting, the literature indicates the important role of the capsule and labrum in maintaining the stability of the hip joint³⁻¹⁵. There is substantial controversy regarding the optimal method for the treatment of this uncommon disorder. Graham and Lapp reported the cases of two patients with recurrent posterior hip dislocations who had marked posterior capsular redundancy³. One of the patients had extensive heterotopic ossification of the hip joint and osteonecrosis of the femoral head. Kim et al. reported on a patient who had a tear in the acetabular labrum that prevented complete reduction of the dislocated hip⁴. The authors reported that it was necessary to remove the labrum, which was widely detached from the anterior to posterior acetabular rim, in order to reduce the hip joint. Townsend et al. reported on three patients with posttraumatic recurrent hip dislocations, two of whom had acetabular dysplasia, who were managed with a posterior bone block⁵. Marti and Kloen described a patient who had a Pipkin type-I fracture that was treated with a posterior acetabuloplasty with an intertrochanteric internal rotation osteotomy⁶. Lieberman et al. repaired the labrum and capsule in a manner analogous to the T-plasty modification of the Bankart procedure for shoulder instability and used a bone block to supplement the soft-tissue reconstruction⁷. However, in the case of their patient, the allograft resorbed by two years and nine months after surgery. Lutter⁸ and Rashleigh-Belcher and Cannon⁹ also used a bone block but reported no absorption at the time of the latest follow-up. Weber and Ganz reported that the fate of the bone block seemed to depend on the type of graft that was used¹⁰. They thought that the complications may have resulted from the operative intervention to repair the hip joint capsule and emphasized the need for a careful and thorough evaluation and treatment of this syndrome. Crowther et al. reported the case of a patient who had recurrent hip dislocation after open reduction and internal fixation of the posterior wall and femoral head fractures¹¹. Because of the posterosuperior wall deficiency, a modified periacetabular osteotomy was performed.

In our review of the literature, we did not identify any case of recurrent dislocation of the hip associated with a dysplastic acetabulum that was treated with periacetabular osteotomy for posterior bone support and enhanced structural stability. Siebenrock et al. treated symptomatic femoroacetabular impingement that was due to acetabular retroversion with periacetabular osteotomy¹⁶ and reported that periacetabular osteotomy

was an effective way to reorient the acetabulum. In the present report, we successfully treated recurrent dislocation of the hip that was associated with mild acetabular dysplasia with capsular repair and periacetabular osteotomy. After two years and six months of follow-up, the patient had an excellent result and was working as a skiing and snowboarding instructor. Although the acetabular dysplasia was not severe, we thought that the combination of a capsular repair and periacetabular osteotomy would be effective because capsular repair alone may not have provided enough stability, especially for a young patient with a dysplastic acetabulum and a very active lifestyle. The fact that the socket was mildly dysplastic, was retroverted, and had a global deficiency is important and probably put the patient at risk for recurrent dislocation. In such cases, strong posterior and lateral bone support may be necessary for the stability of a dysplastic hip joint with recurrent hip dislocation.

To our knowledge, this report is the first to describe the successful treatment of recurrent posterior hip dislocation associated with a dysplastic acetabulum with periacetabular osteotomy. The case described here indicates that acetabular reorientation should be considered for patients with recurrent hip instability and associated acetabular dysplasia.

Appendix

eA Additional images showing the dislocation, the periacetabular osteotomy, and the torn posterior capsule are available with the online version of this article on our web site at jbjs.org. ■

Note: The authors thank John C. Clohisey, MD, for his helpful comments and suggestions.

Yasuhiro Yamanaka, MD

Hiroshi Ito, MD

Teruhisa Hirayama, MD

Hiromasa Tanino, MD

Tatsuya Sato, MD

Takeo Matsuno, MD

Department of Orthopaedic Surgery,

Asahikawa Medical College, Midorigaoka-higashi 2-1,

1-1 Asahikawa, Hokkaido, Japan 078-8510.

E-mail address for Y. Yamanaka: yamanak@asahikawa-med.ac.jp.

E-mail address for H. Ito: itohiro@asahikawa-med.ac.jp.

E-mail address for T. Hirayama: teruhirayama@aol.com.

E-mail address for H. Tanino: tanino@asahikawa-med.ac.jp.

E-mail address for T. Sato: s-tatsu@asahikawa-med.ac.jp.

E-mail address for T. Matsuno: tmatsuno@asahikawa-med.ac.jp

References

1. Thompson VP, Epstein HC. Traumatic dislocation of the hip; a survey of two hundred and four cases covering a period of twenty-one years. *J Bone Joint Surg Am.* 1951;33:746-92.
2. Ito H, Matsuno T, Minami A. Rotational acetabular osteotomy through an Ollier lateral U approach. *Clin Orthop Relat Res.* 2007;459:200-6.
3. Graham B, Lapp RA. Recurrent posttraumatic dislocation of the hip. A report of two cases and review of the literature. *Clin Orthop Relat Res.* 1990;256:115-9.
4. Kim YT, Ninomiya S, Tachibana Y, Tanabe T, Yano Y. Acetabular labrum entrapment following traumatic posterior dislocation of the hip. *J Orthop Sci.* 2003;8:232-5.
5. Townsend RG, Edwards GE, Bazant FJ. Post-traumatic recurrent dislocation of the hip without fracture. In: *Proceedings of the Canadian Orthopaedic Association.* *J Bone Joint Surg Br.* 1969;51:194.
6. Marti RK, Kloen P. Chronic recurrent posterior dislocation of the hip after a Pipkin fracture treated with intertrochanteric osteotomy and acetabuloplasty. A case report. *J Bone Joint Surg Am.* 2000;82:867-72.

- 7.** Lieberman JR, Altchek DW, Salvati EA. Recurrent dislocation of a hip with a labral lesion: treatment with a modified Bankart-type repair. *J Bone Joint Surg Am.* 1993;75:1524-7.
- 8.** Lutter L. Post-traumatic hip redislocation. *J Bone Joint Surg Am.* 1973;55:391-4.
- 9.** Rashleigh-Belcher H, Cannon SR. Recurrent dislocation of the hip with a "Bankart-type" lesion. *J Bone Joint Surg Br.* 1986;68:398-9.
- 10.** Weber M, Ganz R. Recurrent traumatic dislocation of the hip: report of a case and review of the literature. *J Orthop Trauma.* 1997;11:382-5.
- 11.** Crowther JD, Chudik SC, Dahners LE. Periacetabular osteotomy for stabilization of recurrent post-traumatic dislocation of the hip. *J Orthop Trauma.* 2002;16:433-6.
- 12.** Hershey AL, Beals RK. Osteoarticular allograft reconstruction for recurrent post-traumatic dislocation of the hip. *Orthop Rev.* 1994;23:593-7.
- 13.** Liebenberg F, Dommissie GF. Recurrent post-traumatic dislocation of the hip. *J Bone Joint Surg Br.* 1969;51:632-7.
- 14.** Nelson CL. Traumatic recurrent dislocation of the hip. Report of a case. *J Bone Joint Surg Am.* 1970;52:128-30.
- 15.** Sullivan CR, Bickel WH, Lipscomb PR. Recurrent dislocation of the hip. *J Bone Joint Surg Am.* 1955;37:1266-70.
- 16.** Siebenrock KA, Schoeniger R, Ganz R. Anterior femoro-acetabular impingement due to acetabular retroversion. Treatment with periacetabular osteotomy. *J Bone Joint Surg Am.* 2003;85:278-86.

Fig. E1-A Fig. E1-B

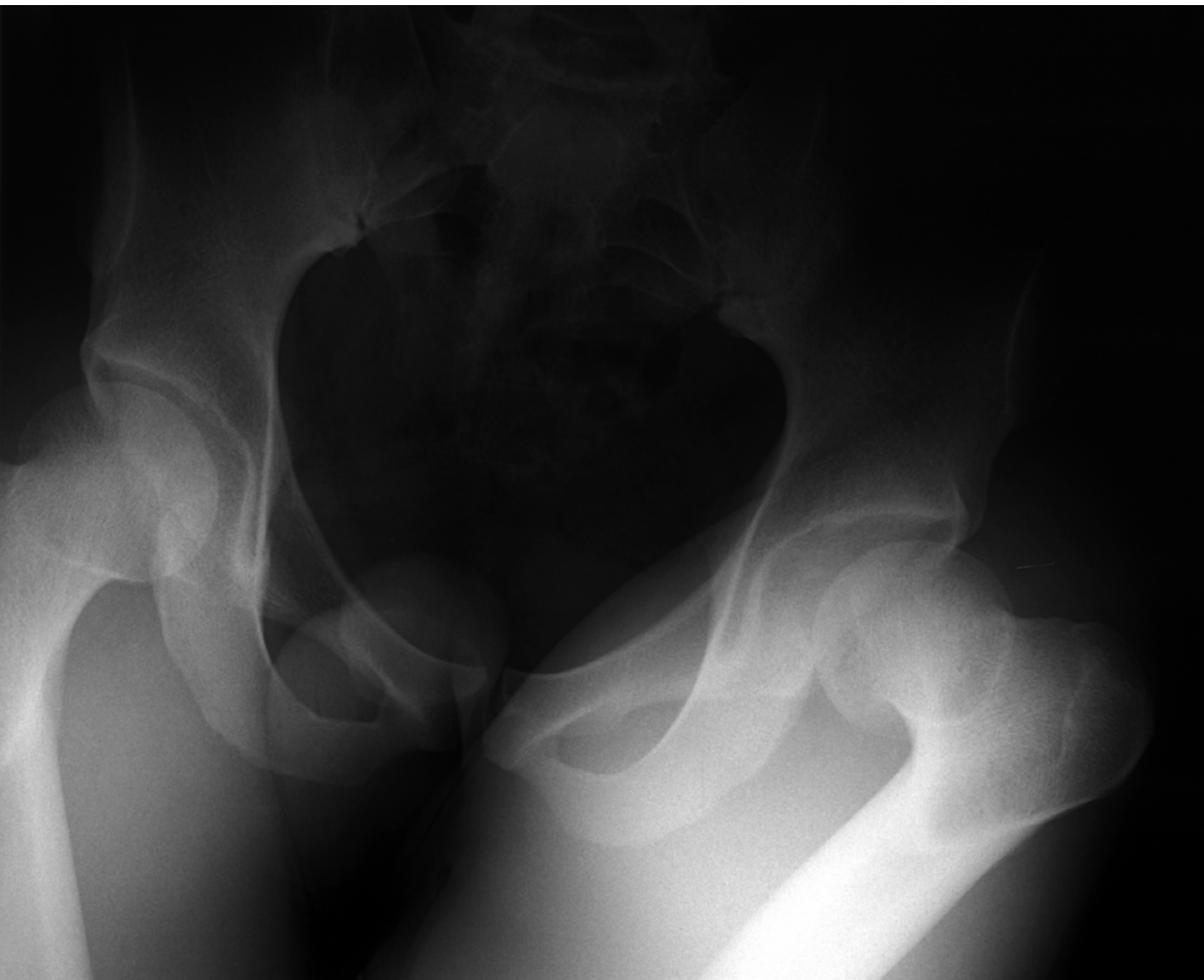
Anteroposterior (Fig. E1-A) and lateral (Fig. E1-B) radiographs showing the second dislocation of the left hip.

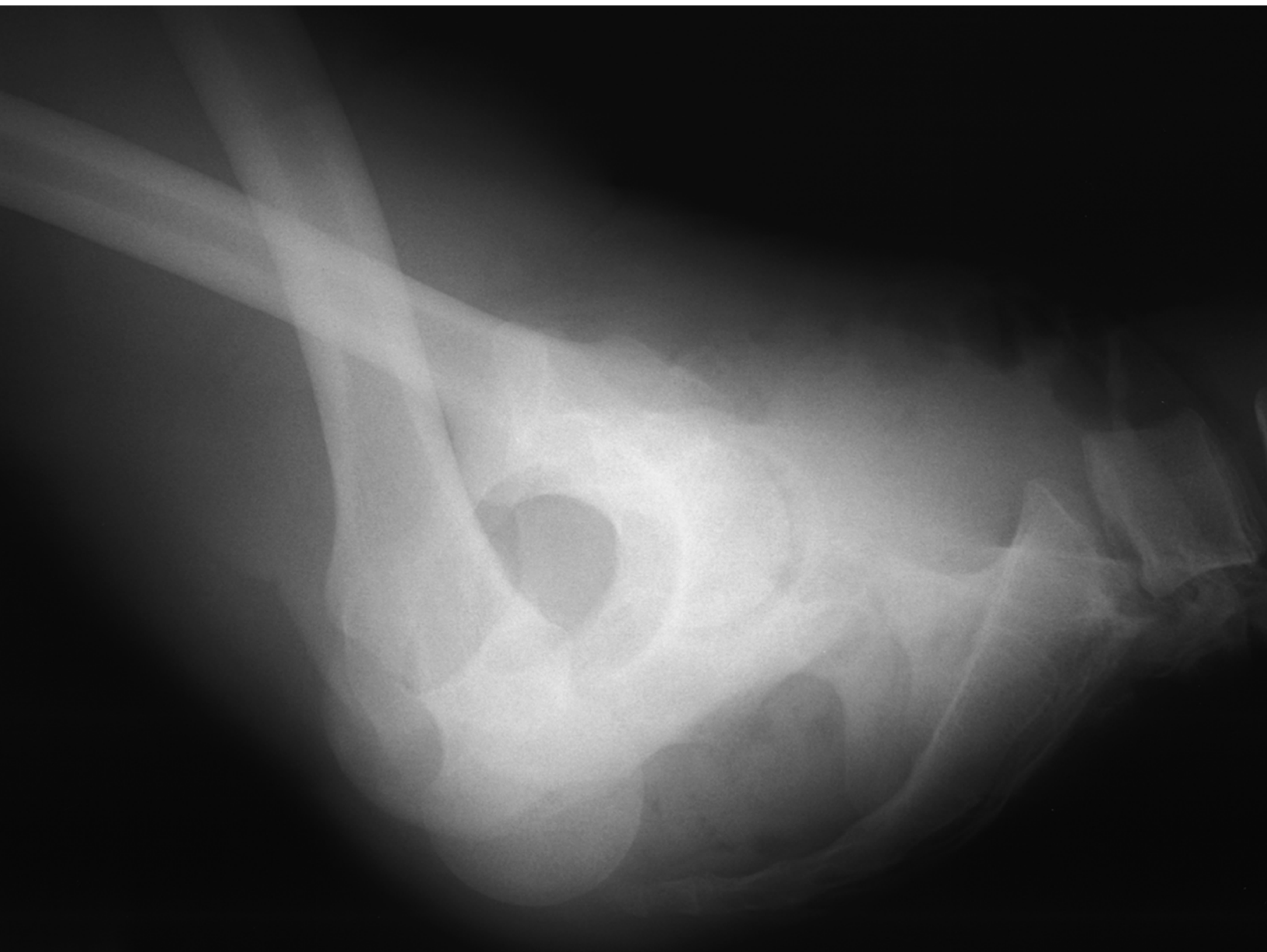
Fig. E-2

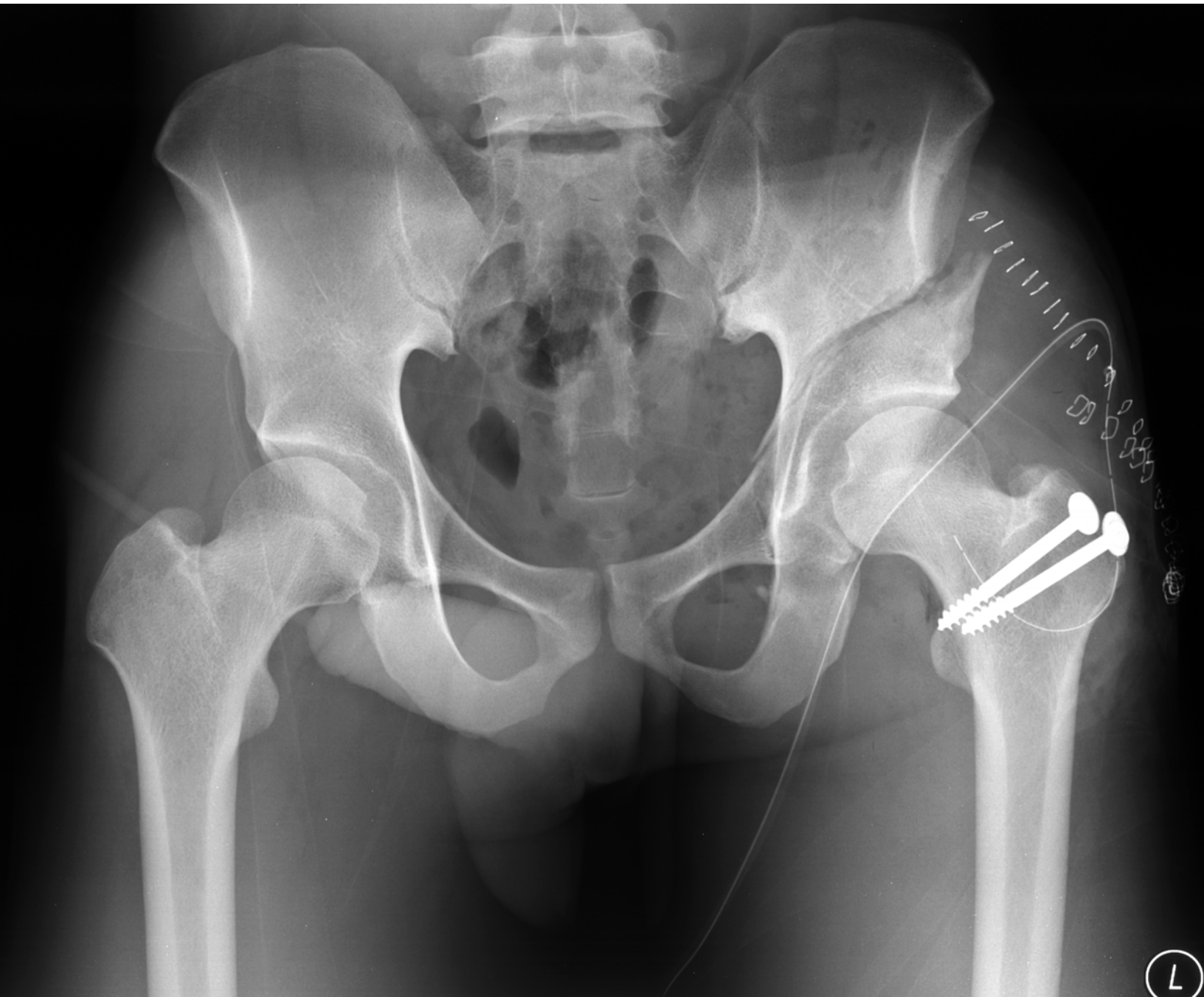
Radiograph made after the modified periacetabular osteotomy.

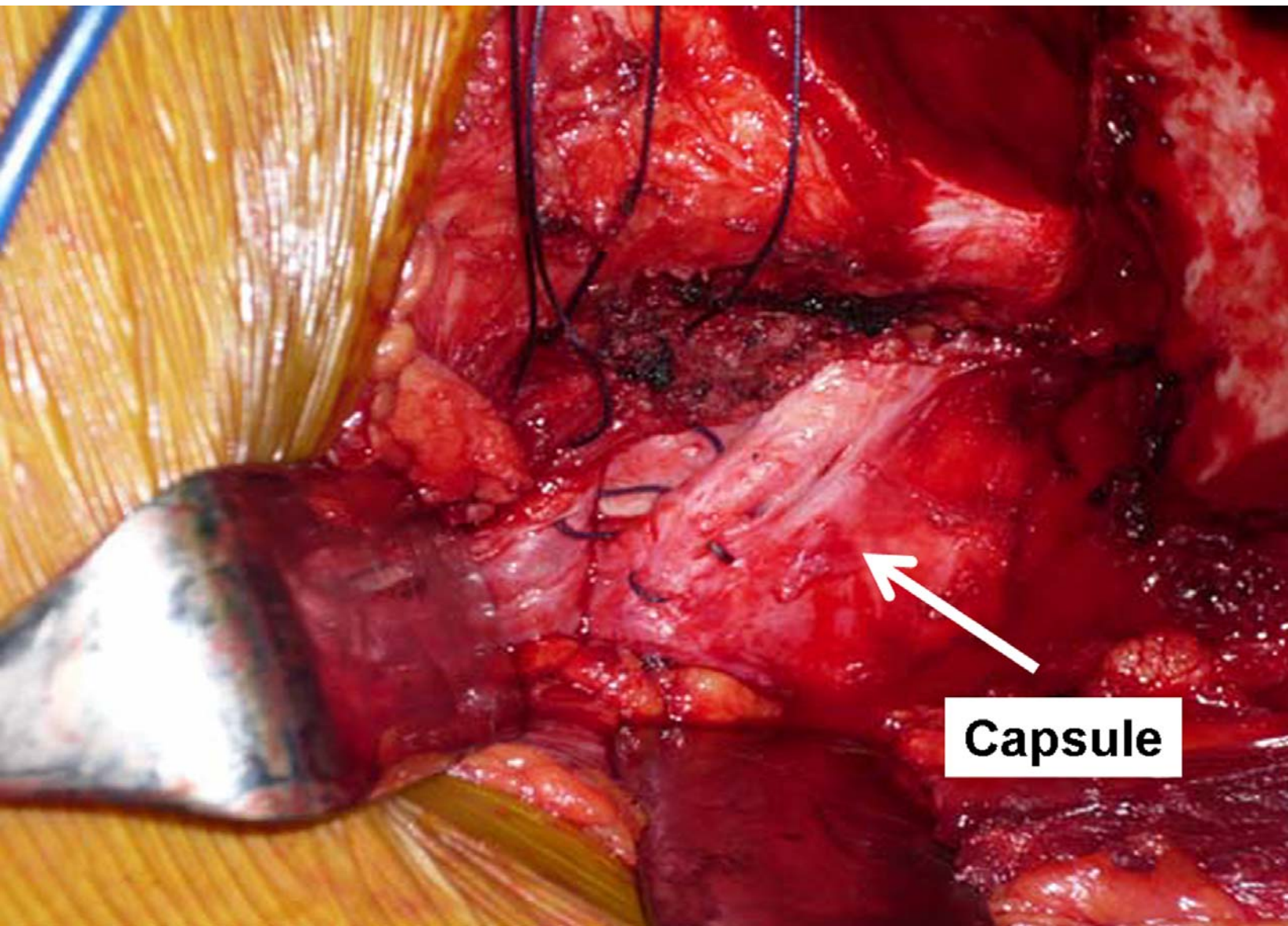
Fig. E-3

Intraoperative photograph showing the torn posterior capsule. The reconstruction was completed with repair of the torn capsule.









Capsule