

AMCoR

Asahikawa Medical College Repository <http://amcor.asahikawa-med.ac.jp/>

Pediatric Research (2005) 57(5 Pt 1):744–748.

Impaired cardiac sympathetic nerve function in patients with Kawasaki disease: comparison with myocardial perfusion

Zhao, Chunlei ; Shuke, Noriyuki ; Yamamoto, Wakako ;
Okizaki, Atsutaka ; Sato, Junichi ; Kajino, Hiroki ; Fujieda,
Kenji ; Aburano, Tamio

Running title:

MIBG Imaging in Kawasaki Disease

Address of correspondence and for reprint request:

Chunlei Zhao, MD

Department of Radiology, Asahikawa Medical College,
2-1 Midorigaoka-Higashi, Asahikawa, 078-8510, Japan

Phone: +81-166-68-2572

Fax: +81-166-68-2579

E-mail: zhaocl@asahikawa-med.ac.jp

**Impaired Cardiac Sympathetic Nerve Function in Patients with Kawasaki Disease:
Comparison with Myocardial Perfusion**

Chunlei Zhao^{1,4},
Noriyuki Shuke¹,
Wakako Yamamoto¹,
Atsutaka Okizaki¹,
Junichi Sato³,
Hiroki Kajino²,
Kenji Fujieda²,
Tamio Aburano¹

¹Department of Radiology and ²Department of Pediatrics, Asahikawa Medical College. ³Section of Radiology, Asahikawa Medical College Hospital, 2-1 Midorigaoka-Higashi, Asahikawa, 078-8510, Japan. ⁴Department of Nuclear Medicine, the Second Affiliated Hospital, Medical College of Zhejiang University, Hangzhou, 310009, China

Abstract

Kawasaki disease (KD) is a leading cause of CAD in children. The impairment of cardiac sympathetic nerve function (CSNF) in the adult patients with coronary artery disease (CAD) could often be seen. However, little is known concerning the impairment of CSNF in KD patients. We investigated CSNF and its relationship with myocardial perfusion in KD patients. Eleven children with KD and 4 controls were studied with ^{123}I -metaiodobenzylguanidine (MIBG) and stressed ^{201}Tl single photon emission computed tomography. By the findings on coronary artery angiography (CAG), the patients were divided into 2 groups: A, without stenosis; B, with significant stenosis and/or old myocardial infarction. CSNF was evaluated from the uptake of ^{123}I -MIBG. While myocardial perfusion was evaluated from ^{201}Tl uptake. The numbers of patients in the groups A and B were 7 and 4. Perfusion defect was found in 0, and 2 patients in group A (0%), and B (50%). ^{123}I -MIBG defects were found in 1 and 4 patients in the group A (14%) and B (100%). There were excellent concordances between the finding of ^{201}Tl and ^{123}I -MIBG in group A. While in group B, the coronary territories with ^{123}I -MIBG defects were significantly more than those with perfusion defects ($P < 0.05$). In KD patients, the impairment of CSNF might be subsequent to coronary artery stenosis and was more severe than the injury of myocardial perfusion.

Key word: Kawasaki disease, cardiac sympathetic nerve function, myocardial perfusion

Abbreviations:

KD, Kawasaki disease

CSNF, cardiac sympathetic nerve function

MIBG, Metaiodobenzylguanidine

SPECT, single photon emission computed tomography

CAG, coronary artery angiography

CAD, coronary artery disease

LV, left ventricle

Introduction

Kawasaki disease (KD) is a syndrome of children and occasionally young adults, manifested by a distinctive erythematous and desquamative exanthem, conjunctivitis, fever and acute vasculitis mainly affects small- and medium-sized arteries, particularly the coronary arteries (1, 2). It is one of the main causes of coronary heart disease in children (3). Extensive cardiac involvement may cause sudden death due to the myocardial infarction (4, 5). However, children with significant coronary involvement due to KD are generally asymptomatic despite significant risk of myocardial infarction (6, 7). Therefore, it is crucial to follow-up and detect coronary artery involvement in the KD patient timely. Coronary artery angiography (CAG) is usually performed to evaluate the involvement of coronary artery. However, CAG can not assess the physiologic status such as the involvement of myocardial ischemia or infarction (8), although it is an accurate method for obtaining anatomic details of large- and medium-sized coronary arteries (9). For evaluating myocardial perfusion, ^{201}Tl and $^{99\text{m}}\text{Tc}$ labeled perfusion tracers have been applied in the patients with KD (10-15). Compared with CAG, perfusion studies could detect perfusion defects even in the absence of coronary abnormalities (1, 16, 17) and seemed to be useful for making decisions on coronary artery bypass surgery, and for predicting the prognosis in KD patients as well (15, 18).

Metaiodobenzylguanidine (MIBG) is a structure analog of norepinephrine (NE) and has the same uptake and storage mechanisms as NE has (19). MIBG is stored in presynaptic vesicles and is secreted in response to acetylcholine released from the preganglionic neuron (20, 21). MIBG labeled with ^{123}I has been generally accepted for assessing cardiac sympathetic nerve function (CSNF) in many diseases, such as coronary artery disease (CAD), heart failure, diabetes, Parkinson's disease, and cardiomyopathy (22-27). In these diseases, decreased cardiac ^{123}I -MIBG uptake was thought to reflect sympathetic denervation. In adult patients with CAD, CSNF impairment could often be seen (28-31). Generally, the areas of reduced MIBG uptake are larger than perfusion defects in myocardial infarction (29-31), indicates the areas of sympathetic denervation not only were limited to the necrotic zones, but also extended to noninfarcted myocardium (29, 31), such lesions are considered to be viable but denervated (30). In the patients with KD, although coronary artery is frequently involved, little is known concerning the injury of CSNF. Therefore, we carried out the present study to investigate CSNF and to clarify its relationship with the involvement of coronary artery in patients with KD.

Materials and Methods

Patients. Eleven children with KD (9 boys, 2 girls; age, 8.6 ± 6.1 yr, range, 0.5-16.1 yr), were studied with ^{123}I -MIBG and stressed ^{201}Tl (either exercise or dipyridamole stress) single-photon emission computed tomography (SPECT) within two weeks without any medical intervention. Their histories of KD ranged from 0.2 to 14.5 years (6.1 ± 6.4 yr). Four age-matched children

(9.5 ± 6.2 yr; range, 4.2-16.3 yr), among which 3 were with acute lymphocyte leukemia without myocardial impairment post chemotherapy and 1 was with glycogen storage disease (type IX), were examined with both the imaging and served as controls. None of the controls has chest pain and abnormal finding in electrocardiogram. The hospital ethical committee approved the study and all the children or their parents gave informed consents before the study.

According to the finding of CAG and the history, patients were classified into 2 groups. Group A comprised the patients without present or past coronary artery stenosis; Group B comprised the patients with significant coronary artery stenosis and/or history of myocardial infarction.

By referring to the nomenclature of standardized myocardial segmentation for tomographic imaging by American Heart Association (32), left ventricle (LV) was divided into 3 coronary territories corresponding to left anterior descending branch, left circumflex branch, and right coronary artery as shown in figure 1.

Coronary Angiography. Coronary angiography was performed within 1 month of ^{201}Tl and ^{123}I -MIBG imaging in 10 patients, and within 1 year in 1 patient. A coronary aneurysm was defined when the diameter of the coronary artery was 1.5 times greater than that of the adjacent vessel. Slight dilation of the coronary artery less than this criterion was considered as normal. Significant coronary artery stenosis was defined as $\geq 75\%$ stenosis of the coronary artery lumen.

Imaging Protocol. For both ^{201}Tl and ^{123}I -MIBG imaging, data were obtained using a single-headed rotating gamma camera equipped with a low-energy general-purpose collimator (RC-135E, Hitachimedico, Tokyo, Japan). The full width of half maximum (FWHM) of this system is 9.6 mm for 100 mm radius of rotation in the air. All patients fasted on the day of study and continued to fast until the study was completed.

In ^{123}I -MIBG study, 1.85MBq/kg ^{123}I -MIBG (MyoMIBG-I-123®, 111 MBq/0.03-0.10 mg, Daiichi Radioisotope Laboratory, Tokyo, Japan) was intravenously injected. With this tracer, the absorbed dose in organs of a 5 years old child are 0.055 mGy/MBq in heart, 0.18 in liver, 0.036 in kidneys, 0.018 in testes, 0.025 in ovaries and the effective dose is 0.037 mSv/MBq (33). Early imaging began at 15 min after the injection. Thirty-two projections were obtained on a 64×64 matrix for 40 sec, with a 180 degree rotation and an energy window of 10% centered at 160 KeV. Four hrs later, delayed imaging was performed under the same acquisition conditions as used in the early imaging.

Exercise-stress ^{201}Tl imaging was performed in 7 patients using an exercise protocol. Patients performed exercise on a bicycle ergometer (BE-360 Well Bike, Fukuda Denshi, Tokyo, Japan), which started at 50 watt and successively increased by 25 watt every 3 minutes until the occurrence of fatigue or reaching $\geq 85\%$ age-predicted heart rate. Six patients fulfilled the exercise testing and one patient was terminated for the occurrence of ventricular tachycardia. At

1 minute before the termination of the exercise, 1.85 MBq/kg ^{201}Tl (Thallium Chloride-201, Daiichi Radioisotope Laboratory, Tokyo, Japan) was intravenously injected. With this tracer, the absorbed dose in organs of a 5 years old child are 0.62 mGy/MBq in heart, 0.45 in liver, 1.2 in kidneys, 9.6 in testis, 3.5 in ovary and the effective dose is 1.7 mSv/MBq (33). At 15 min after the injection, 32 projections were obtained on a 64×64 matrix for 30 seconds, with a 180 degree rotation and an energy window of 20% centered at 70 KeV. The rest ^{201}Tl imaging was performed at 4 h after the injection using the same acquisition conditions as used in the stress study. For 4 patients including 3 infantile patients who were unable to undergo the exercise-stress, dipyridamole was administrated intravenously for 4 minutes with a dose of 0.56mg/kg. The 12-lead electrocardiogram was recorded at 1-minute intervals throughout the infusion. Three minutes after dipyridamole infusion, 1.85 MBq/kg ^{201}Tl was given. Stress imaging was performed at 15 minutes post-injection and rest imaging was performed 4 hrs later with the same acquisition conditions as used in the exercise-stressed study.

Image reconstruction was performed without attenuation and scatter correction by a filtered back projection algorithm for both ^{123}I -MIBG and ^{201}Tl studies. After preprocessing with a Butterworth filter (cutoff frequency, 0.44 cycle/cm; order, 8), transaxial images were reconstructed with a ramp filter. Long- and short-axial slices were then produced by axial reorientation.

Data analysis. Uptake of ^{201}Tl and ^{123}I -MIBG were evaluated from tomographic images by 2 experienced observers for the three coronary territories by referring to the quantitative color scale setting the highest uptake of LV as 100%. In both studies, an uptake $\geq 60\%$ highest uptake of LV was defined as within the normal range. In either early or delayed ^{123}I -MIBG studies, ^{123}I -MIBG defect was defined as an uptake $< 60\%$ highest uptake of LV. In stressed and rest ^{201}Tl imaging, myocardial ischemia was defined as an uptake $< 60\%$ highest uptake of LV in stressed study but $\geq 60\%$ highest uptake of LV in rest study. While myocardial damage was defined as an uptake $< 60\%$ highest uptake of LV in both stressed and rest studies. Both myocardial ischemia and damage were defined as perfusion defect. The coronary territories with perfusion defect and ^{123}I -MIBG defect were counted for every patient.

Statistical Analysis. The concordance between the coronary territories with ^{123}I -MIBG defects and those with perfusion defects in the patients was investigated by McNemar's test. A $P < 0.05$ was considered statistically significant.

Results

No perfusion and ^{123}I -MIBG defect was found in controls.

The clinical and imaging information of the patients were listed in Table 1. Group A and B consisted of 7 and 4 patients. Three patients in group B had histories of myocardial infarction. Myocardial perfusion defect was found in 0 and 2 patients in group A (0%) and B (50%),

respectively. While ^{123}I -MIBG defects were found in 1 patient in group A (14.3%) and 4 patients in group B (100%). Among 12 coronary territories in group B, 7 had stenosis and/or histories of myocardial infarction. All these 7 coronary territories had ^{123}I -MIBG defects. While perfusion defect was found only in 3 of them. Among the left 5 coronary territories with normal coronary artery or with aneurysm alone in group B, 2 had ^{123}I -MIBG defects and none had myocardial perfusion defect.

Figure 2 shows the bull's-eye maps of the uptake in exercise-stressed and rest ^{201}Tl imaging, early and delayed ^{123}I -MIBG imaging of a control and a patient in group B. The area with ^{123}I -MIBG defect was significantly larger than that with perfusion defect in the patient.

Concordance of ^{201}Tl and ^{123}I -MIBG findings in the patients with KD. The coronary territories with myocardial perfusion defects and ^{123}I -MIBG defects are shown in Table 2. Significant discordance between the coronary territories with perfusion defects and those with ^{123}I -MIBG defects was found in group B ($P < 0.05$), but not in group A.

Discussion

KD is a leading cause of acquired heart disease in children (3, 34). According to the cohort study by Kato et al, coronary aneurysm occurred in 25% patients with acute KD, of which 55% showed regression. During the follow-up, ischemic heart disease developed in 4.7%, myocardial infarction in 1.9%, and death in 1.8% (1).

In the KD patient, although the involvement of coronary artery is a main sequela, little is known so far concerning the impairment of CSNF. Therefore, we carried out the present study to investigate the CSNF and its relation with myocardial perfusion in KD patients. Our study found that CSNF was significantly damaged in the KD patients with coronary artery stenosis and/or the history of myocardial infarction.

All coronary territories in group A had no myocardial perfusion defect and only one coronary territory had slight ^{123}I -MIBG defect, indicating that myocardial perfusion and CSNF were kept well in the KD patients without present or past coronary artery stenosis. Among 5 coronary territories without present or past stenosis in group B, no coronary territory was found with perfusion defect and 2 coronary territories were found with ^{123}I -MIBG defects. There were totally 6 coronary territories with aneurysm but without stenosis in group A and B. However, only 2 of them were found with ^{123}I -MIBG defect. Considering that the occurrence of ^{123}I -MIBG defect were not in good accordance with aneurysm, coronary aneurysm alone seemed to be not closely associated with the impairment of CSNF in the patients with KD.

As opposed to the excellent concordance between the findings in ^{201}Tl and ^{123}I -MIBG studies in the group A, the coronary territories with ^{123}I -MIBG defects were significantly more than those with perfusion defects in group B. Less perfusion defects compared to ^{123}I -MIBG defects found in group B suggested that even if myocardial perfusion recovered or was

improved by either the formation of coronary collateral branches or re-perfusion therapy, the impairment of CSNF still remained. Cardiac adrenergic tissue is very sensitive to ischemia (35, 36). Myocardial ischemia could promote denervation in the area surrounding ischemic lesions and sympathetic nerve is thought to be more susceptible than cardiac muscle cell to permanent ischemic damage (31). In CAD patients after percutaneous transluminal coronary angioplasty, although partial re-innervation could be seen sometimes in the area with well patent coronary artery, ^{123}I -MIBG defect remained wider than the ischemia-induced or scar-associated perfusion defect (37). Considering the finding of more ^{123}I -MIBG defects than perfusion defects and the histories of the patients in group B, the impairment of CSNF in KD patients, likely sharing the same mechanism as that in the adult patients with CAD, is subsequent to the ischemia caused by the formation of coronary artery stenosis.

We noticed that 3 coronary territories with ^{123}I -MIBG defects but without perfusion defect in our patients had neither present nor past coronary artery stenosis. Because sympathetic nerve is very sensitive to ischemia and might be more susceptible to cardiac muscle cell (31, 35, 36), the ^{123}I -MIBG defects in these coronary territories may reflect slight or latent ischemia, although reduced myocardial perfusion could not be detected presently. The speculation that ^{123}I -MIBG imaging is capable for detecting early staged or latent ischemia in the KD patients needs to be verified by further investigation and the data of follow-up.

Compared to most patients in groups A, patients in group B had long KD histories, ranged from 11.3 to 14.5 years. A patient in group A, although also had a long KD history of 8 years, showed neither perfusion nor ^{123}I -MIBG defect. Therefore, it is hard to say the length of KD history, if without accompanying with stenosis, may directly affect CSNF.

Limitations of the study. The resolution of our imaging system is 9.6 mm FWHM for 100 mm radius of rotation. Because the FWHM in an ordinary myocardial SPECT study is around 15 mm (38), the resolution of our system is thought to be sufficient for imaging myocardium in most examinee. In pediatric patients with small hearts, although quantification of electrocardiographically gated SPECT has been considered to be inaccurate (38), qualitative assessment of myocardial perfusion has been considered with no special problem and generally applied in pediatric KD patients (10-15). In addition, to improve the image quality in 3 infantile patients in the study, a smaller radius of camera and non-circular orbit were used in the data acquisition by referring to the reported method (38).

In this study, the defects of ^{201}Tl and ^{123}I -MIBG were arbitrarily defined as less than 60% of the highest LV uptake. According to this criterion, perfusion abnormalities were found only in 2 patients in the group B. However, in previous studies of Paridon and Fu, high incidence of perfusion defect were found by visual evaluation in the KD patients (13, 16). In our study, a slightly decreased uptake but still more than 60% of the highest LV uptake were recognized as normally perfusion. While it might be determined as perfusion defect in their visual evaluation.

Therefore, our criterion may underestimate the perfusion abnormality to some extent compared to their visual evaluation. However, since the same criterion was used in ^{123}I -MIBG imaging as well in this study, the influence of the underestimation on the tracers' uptake might be counteracted between ^{201}Tl and ^{123}I -MIBG studies.

Because ^{123}I -MIBG imaging has not been routinely used in the children with KD, only 11 patients were enrolled in this study. The small amount of the subjects might inevitably bring the statistical uncertainty. Although our data was somewhat insufficient, the results appeared to be valuable for the understanding of the pathophysiology of KD from a new point of view.

Clinical implication. Our study found CSNF was impaired in KD patients with coronary stenosis and/or myocardial infarction and suggested that the impairment of CSNF might be subsequent to the coronary artery stenosis in the patient with KD. In KD patients, ^{123}I -MIBG defect appeared to be a clear evidence of sympathetic denervation following not only present but also past ischemia or infarction, as found in CAD patients (39).

Miyagawa et al reported that the perfusion study could provide more accurate prognosis than CAG in the patient with KD (18). However, the prognostic value of ^{123}I -MIBG imaging in KD patients is unknown so far.

In this first-step investigation on CSNF in KD patients, due to the small amount of the patients and the lack of follow-up data, the relationship between the clinical manifestation and the impairment of CSNF is hard to be clarified for many aspects. The clinical significance of ^{123}I -MIBG imaging in KD patients, such as its prognosis value, remains to be investigated.

Conclusion

Our preliminary study suggested that in the patients with KD, the impairment of CSNF might be subsequent to the formation of coronary artery stenosis. In KD patients with significant coronary artery stenosis and/or the history of myocardial infarction, the impairment of CSNF was more severe than that of myocardial perfusion.

Reference

1. Kato H, Sugimura T, Akagi T, Sato N, Hashino K, Maeno Y, Kazue T, Eto G, Yamakawa R 1996 Long-term consequences of Kawasaki disease. A 10- to 21-year follow-up study of 594 patients. *Circulation* 94:1379-1385
2. Faller DV 1996 Diseases of lymph nodes and spleen. In: Bennett JC, Plum F (eds) *Cecil Textbook of Medicine*. W.B. Saunders, Philadelphia, pp 968-974
3. Rowley AH, Shulman ST 1999 Kawasaki syndrome. *Pediatr Clin North Am* 46:313-329
4. Fujiwara H, Hamashima Y 1978 Pathology of the heart in Kawasaki disease. *Pediatrics* 61:100-107
5. Kato H, Koike S, Yamamoto M, Ito Y, Yano E 1975 Coronary aneurysms in infants and young children with acute febrile mucocutaneous lymph node syndrome. *J Pediatr* 86:892-898
6. Allen SW, Shaffer EM, Harrigan LA, Wolfe RR, Glode MP, Wiggins JW 1992 Maximal voluntary work and cardiorespiratory fitness in patients who have had Kawasaki syndrome. *J Pediatr* 121:221-225
7. Paridon SM, Ross RD, Kuhns LR, Pinsky WW 1990 Myocardial performance and perfusion during exercise in patients with coronary artery disease caused by Kawasaki disease. *J Pediatr* 116:52-56
8. Hamaoka K, Onouchi Z, Kamiya Y, Sakata K 1998 Evaluation of coronary flow velocity dynamics and flow reserve in patients with Kawasaki disease by means of a Doppler guide wire. *J Am Coll Cardiol* 31:833-840
9. Schillaci O, Lagana B, Danieli R, Gentile R, Tubani L, Baratta L, Scopinaro F 1999 Technetium-99m sestamibi single-photon emission tomography detects subclinical myocardial perfusion abnormalities in patients with systemic lupus erythematosus. *Eur J Nucl Med* 26:713-717
10. Kondo C, Hiroe M, Nakanishi T, Takao A 1989 Detection of coronary artery stenosis in children with Kawasaki disease. Usefulness of pharmacologic stress 201Tl myocardial tomography. *Circulation* 80:615-624
11. Spielmann RP, Nienaber CA, Hausdorf G, Montz R 1987 Tomographic myocardial perfusion scintigraphy in children with Kawasaki disease. *J Nucl Med* 28:1839-1843.
12. Jan SL, Hwang B, Fu YC, Lee PC, Kao CH, Liu RS, Chi CS 2000 Comparison of 201Tl SPET and treadmill exercise testing in patients with Kawasaki disease. *Nucl Med Commun* 21:431-435
13. Fu YC, Kao CH, Hwang B, Jan SL, Chi CS 2002 Discordance between dipyridamole stress Tc-99m sestamibi SPECT and coronary angiography in patients with Kawasaki disease. *J Nucl Cardiol* 9:41-46

14. Fukuda T, Ishibashi M, Yokoyama T, Otaki M, Shinohara T, Nakamura Y, Miyake T, Kudoh T, Oku H 2002 Myocardial ischemia in Kawasaki disease: evaluation with dipyridamole stress technetium 99m tetrofosmin scintigraphy. *J Nucl Cardiol* 9:632-637
15. Schillaci O, Banci M, Scopinaro F, Tavolaro R, Villotti G, De Vincentis G, Ventriglia F, Borgia MC, Colella AC, Colloridi V 1995 Myocardial scintigraphy with 99mTc-sestamibi in children with Kawasaki disease. *Angiology* 46:1009-1014
16. Paridon SM, Galioto FM, Vincent JA, Tomassoni TL, Sullivan NM, Bricker JT 1995 Exercise capacity and incidence of myocardial perfusion defects after Kawasaki disease in children and adolescents. *J Am Coll Cardiol* 25:1420-1424
17. Fukazawa M, Fukushige J, Takeuchi T, Narabayashi H, Igarashi H, Hijii T, Ueda K, Kuwabara Y, Otsuka M, Ichiya Y 1993 Discordance between thallium-201 scintigraphy and coronary angiography in patients with Kawasaki disease: myocardial ischemia with normal coronary angiogram. *Pediatr Cardiol* 14:67-74
18. Miyagawa M, Mochizuki T, Murase K, Tanada S, Ikezoe J, Sekiya M, Hamamoto K, Matsumoto S, Niino M 1998 Prognostic value of dipyridamole-thallium myocardial scintigraphy in patients with Kawasaki disease. *Circulation* 98:990-996
19. Valette H, Syrota A 1998 Nuclear techniques in the assessment of myocardial innervation. In: Murry IPC, Ell PJ (eds) *Nuclear Medicine in Clinical Diagnosis and Treatment*. Churchill Livingstone, Edinburgh, pp 1525-1529
20. Wieland DM, Brown LE, Tobes MC, Rogers WL, Marsh DD, Mangner TJ, Swanson DP, Beierwaltes WH 1981 Imaging the primate adrenal medulla with [123I] and [131I] meta-iodobenzylguanidine: concise communication. *J Nucl Med* 22:358-364
21. Jaques S, Jr., Tobes MC, Sisson JC, Baker JA, Wieland DM 1984 Comparison of the sodium dependency of uptake of meta-iodobenzylguanidine and norepinephrine into cultured bovine adrenomedullary cells. *Mol Pharmacol* 26:539-546
22. Atsumi H, Takeishi Y, Fujiwara S, Tomoike H 1998 Cardiac sympathetic nervous disintegrity is related to exercise intolerance in patients with chronic heart failure. *Nucl Med Commun* 19:451-456
23. Murata K, Sumida Y, Murashima S, Matsumura K, Takeda H, Nakagawa T, Shima T 1996 A novel method for the assessment of autonomic neuropathy in type 2 diabetic patients: a comparative evaluation of 123I-MIBG myocardial scintigraphy and power spectral analysis of heart rate variability. *Diabet Med* 13:266-272
24. Iwasa K, Nakajima K, Yoshikawa H, Tada A, Taki J, Takamori M 1998 Decreased myocardial 123I-MIBG uptake in Parkinson's disease. *Acta Neurol Scand* 97:303-306
25. Murata K, Kusachi S, Murakami T, Nogami K, Murakami M, Hirohata S, Tominaga Y, Komatsubara I, Tsuji T 1997 Relation of iodine-123 metaiodobenzylguanidine myocardial scintigraphy to endomyocardial biopsy findings in patients with dilated

- cardiomyopathy. *Clin Cardiol* 20:61-66
26. Ueda T, Kusachi S, Yamaji H, Morishita N, Mima T, Imai M 1997 Recovery of iodine-123 metaiodobenzylguanidine uptake associated with left ventricular functional recovery in a patient with dilated cardiomyopathy. Endomyocardial histological findings before and after the improvement of uptake. *Jpn Heart J* 38:145-150
 27. Yoshimura N, Kimura M, Ozaki T, Takahashi N, Sakai K 1998 [Two patients with hypertrophic cardiomyopathy showing regionally increased washout of 123I-MIBG from the thick myocardium]. *Kaku Igaku* 35:315-320
 28. Stanton MS, Tuli MM, Radtke NL, Heger JJ, Miles WM, Mock BH, Burt RW, Wellman HN, Zipes DP 1989 Regional sympathetic denervation after myocardial infarction in humans detected noninvasively using I-123-metaiodobenzylguanidine. *J Am Coll Cardiol* 14:1519-1526
 29. McGhie AI, Corbett JR, Akers MS, Kulkarni P, Sills MN, Kremers M, Buja LM, Durant-Reville M, Parkey RW, Willerson JT 1991 Regional cardiac adrenergic function using I-123 meta-iodobenzylguanidine tomographic imaging after acute myocardial infarction. *Am J Cardiol* 67:236-242
 30. Ishida Y, Maeno M, Hirose Y, Takahashi N, Katabuchi T, Oka H, Hayashida K, Takamiya M, Nonogi H, Miyatake K 1995 [Characteristics of regional sympathetic dysfunction in acutely ischemic myocardium assessed by 123I-metaiodobenzylguanidine imaging: impairment of myocardial norepinephrine uptake or retention]. *Kaku Igaku* 32:631-642
 31. Matsuo S, Takahashi M, Nakamura Y, Kinoshita M 1996 Evaluation of cardiac sympathetic innervation with iodine-123-metaiodobenzylguanidine imaging in silent myocardial ischemia. *J Nucl Med* 37:712-717
 32. Cerqueira MD, Weissman NJ, Dilsizian V, Jacobs AK, Kaul S, Laskey WK, Pennell DJ, Rumberger JA, Ryan T, Verani MS 2002 Standardized myocardial segmentation and nomenclature for tomographic imaging of the heart: a statement for healthcare professionals from the Cardiac Imaging Committee of the Council on Clinical Cardiology of the American Heart Association. *J Nucl Cardiol* 9:240-245
 33. 1998 Radiation dose to patients from radiopharmaceuticals (addendum 2 to ICRP publication 53). *Ann ICRP* 28:1-126
 34. Taubert KA, Rowley AH, Shulman ST 1994 Seven-year national survey of Kawasaki disease and acute rheumatic fever. *Pediatr Infect Dis J* 13:704-708
 35. Hartikainen J, Mustonen J, Kuikka J, Vanninen E, Kettunen R 1997 Cardiac sympathetic denervation in patients with coronary artery disease without previous myocardial infarction. *Am J Cardiol* 80:273-277
 36. Simula S, Vanninen E, Viitanen L, Kareinen A, Lehto S, Pajunen P, Syvanne M, Kuikka

- J, Laakso M, Hartikainen J 2002 Cardiac adrenergic innervation is affected in asymptomatic subjects with very early stage of coronary artery disease. *J Nucl Med* 43:1-7
37. Guertner C, Klepzig H, Jr., Maul FD, Hartmann A, Lebach S, Hellmann A, Hoer G 1993 Noradrenaline depletion in patients with coronary artery disease before and after percutaneous transluminal coronary angioplasty with iodine-123 metaiodobenzylguanidine and single-photon emission tomography. *Eur J Nucl Med* 20:776-782
38. Nakajima K, Taki J, Higuchi T, Kawano M, Taniguchi M, Maruhashi K, Sakazume S, Tonami N 2000 Gated SPET quantification of small hearts: mathematical simulation and clinical application. *Eur J Nucl Med* 27:1372-1379
39. Dae MW, Herre JM, O'Connell JW, Botvinick EH, Newman D, Munoz L 1991 Scintigraphic assessment of sympathetic innervation after transmural versus nontransmural myocardial infarction. *J Am Coll Cardiol* 17:1416-1423

Legend of Figures

Figure 1.

Diagram of coronary territories of left ventricle on short axial plane. LAD = left anterior descending branch; LCx = left circumflex branch; RCA = right coronary artery.

Figure 2.

The bull's-eye maps of stressed and rest ^{201}Tl uptake, early and delayed ^{123}I -MIBG uptake of a 5-y-old control boy (A) and a 14-y-old boy with Kawasaki disease in the group B (B). In the patient, the area with ^{123}I -MIBG defect is significantly larger than that with ^{201}Tl defect.

Table 1. Angiography, ¹²³I-MIBG and ²⁰¹Tl SPECT data in the patients with Kawasaki disease (KD)

Case	Sex	Age at Study (y)	Hx of KD (y)	Lesions in coronary angiography			CT with Defects in E&D ¹²³ I-MIBG SPECT	CT with PD in ²⁰¹ Tl SPECT
				RCA	LAD	LCx		
Group A								
1	m	0.6	0.3	N	N	N	-	-
2	f	1.4	0.3	N	N	N	-	-
3	m	0.5	0.2	N	N	N	-	-
4	f	5.9	3.2	N	N	N	-	-
5	m	6.5	0.3	N	N	N	-	-
6	m	8.3	0.4	A (4.9mm)	A (5.5mm)	N	RCA	-
7	m	10.5	8.0	N	N	A (4.8mm)	-	-
Group B								
1	m	15.1	14.5	OMI, S, CV	A (8.0mm)	N	RCA	-
2	m	14.8	13.7	A (5.5mm)	OMI, S, RC	S	RCA, LAD, LCx	LAD
3	m	15.1	11.3	OMI, S, PBP	OMI, S, PBP	A (6.7mm)	RCA, LAD	RCA, LAD
4	m	16.1	14.4	S and 2A (6.2/7.1mm)	S and 2A (7.3/11.4mm)	N	RCA, LAD, LCx	-

Hx, history; RCA, right coronary artery; LAD, left anterior descending branch; LCx, left circumflex branch; E&D, early and delayed; SPECT, single photon emission computed tomography; PD, perfusion defect; CT, coronary territory; N, normal; A (mm), aneurysm (maximum diameter); S, stenosis; OMI, old myocardial infarction; CV, collateral vessel formation; PBP, post by-pass operation; RC, recanalization; -, negative finding

Table 2. Concordance of the coronary territories with ¹²³I-MIBG defect and those with perfusion defect in the patients

		Coronary territories with ¹²³ I-MIBG defect					
		Group A			Group B		
		Yes	No	Total	Yes	No	Total
Coronary territories	Yes	0	0	0	3	0	3
with perfusion defect	No	1	20	21	6	3	9
Total		1	20	21	9	3	12
χ^2				-			-
P value (by exact test)				=1			=0.03125

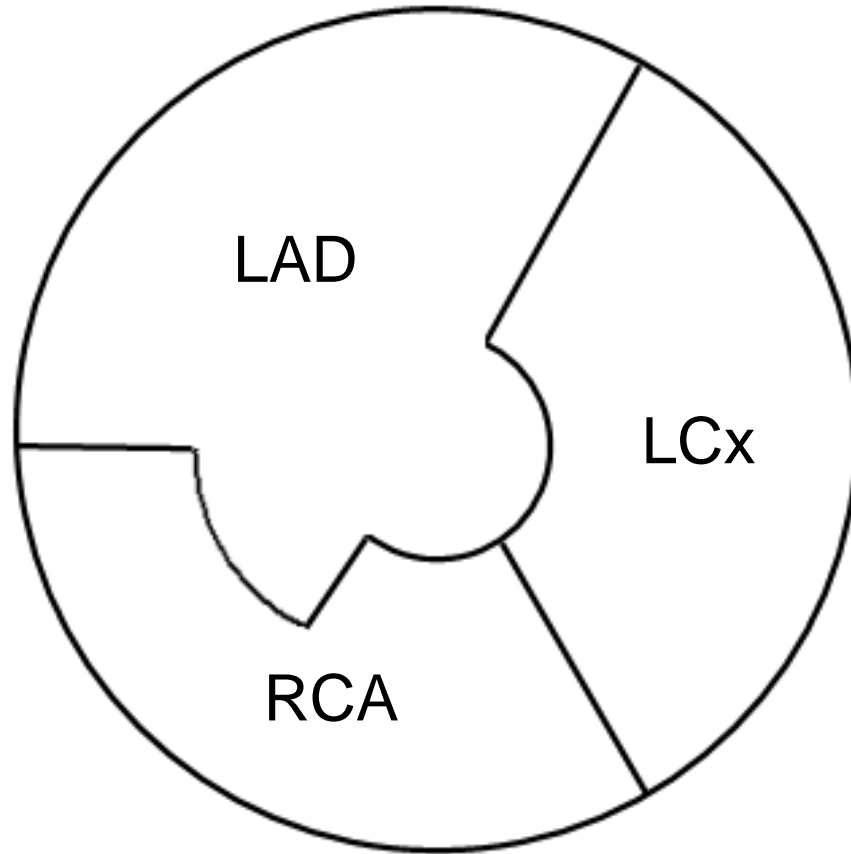


Figure 1

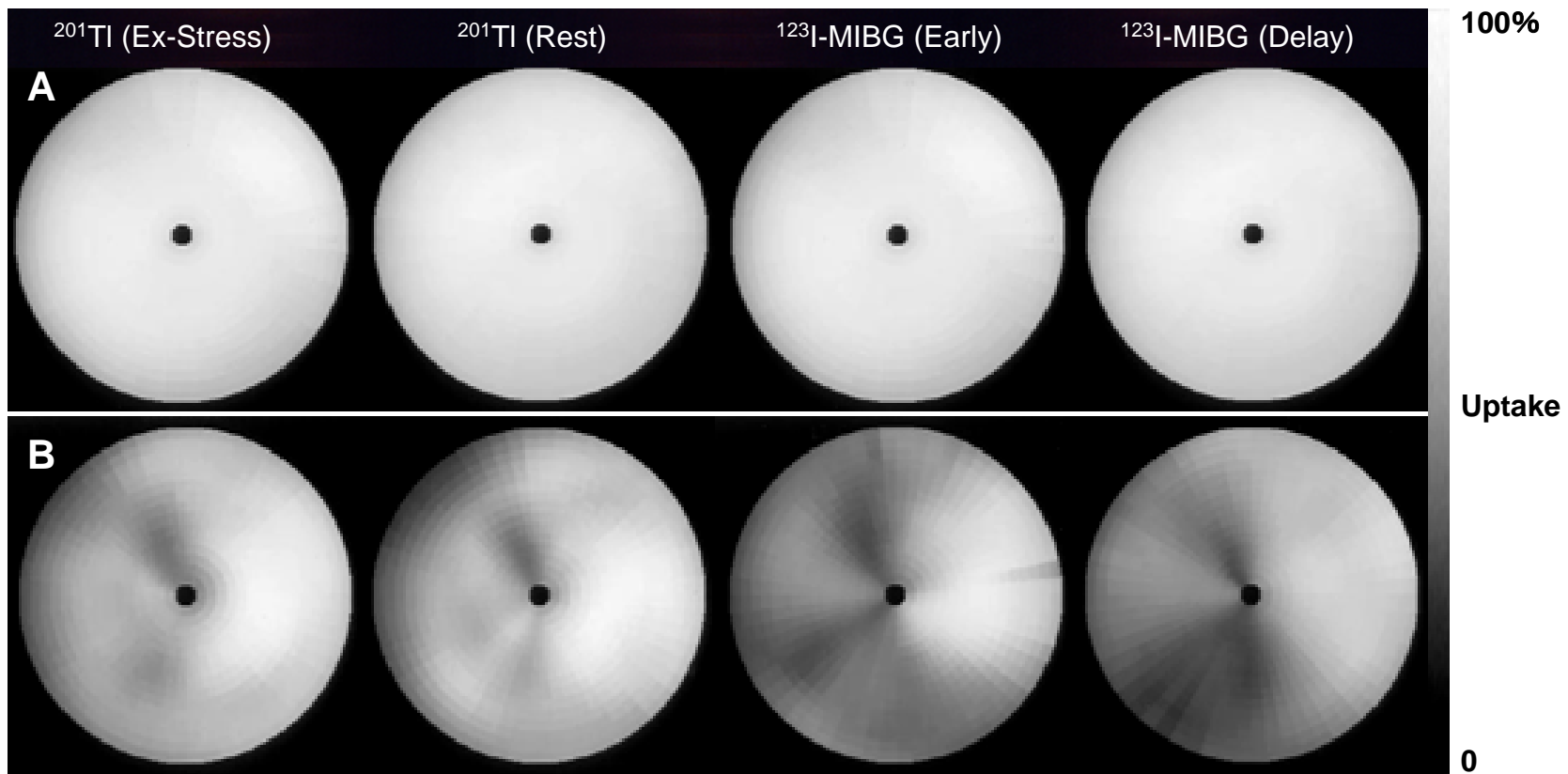


Figure 2