

AMCoR

Asahikawa Medical College Repository <http://amcor.asahikawa-med.ac.jp/>

ANNALS OF THORACIC SURGERY (2000) 69-4:1264-1266.

Konno procedure for infective endocarditis involving aortic valve in a small child

Goh, K; Yamamoto, H; Tsuda, N; Sasajima, T

Konno Procedure for Infective Endocarditis Involving Aortic Valve in a Small Child

Short Title : Konno Procedure for Infectious Endocarditis

Kazutomo Goh, MD, Hiroshi Yamamoto, MD, Nobuyuki Akasaka, MD,
Naoya Tsuda, MD*, Tokitsugi Hayashi, MD*, and Tadahiro Sasajima, MD

First Department of Surgery and First Department of Pediatrics*,
Asahikawa Medical College,
Asahikawa, Japan

Address reprint requests to Dr Goh, First Department of Surgery,
Asahikawa Medical College, Nishikagura 4-5-3-11, Asahikawa 078, Japan
Telephone: (81)166-65-2111 Fax: (81)166-65-4845
e-mail: kgoh@asahikawa-med.ac.jp

Abstract

The Konno procedure was performed to replace the aortic valve and the sinus of Valsalva in a 1-year-old child with pneumococcal infective endocarditis. A Dacron (C.R. Bard, Haverhill, PA) graft and a 16 mm ATS valve (ATS Medical Inc., Minneapolis, MN) was used. Adequate debridement could be easily performed. Postoperative recovery was uneventful. The procedure, originally developed for narrow aortic annulus, could be a good option for treatment of a young individual with aortic valve endocarditis.

Keywords: Konno, Endocarditis, Aortic valve, Pneumococcus.

Although infective endocarditis is uncommon in general pediatric population, patients with congenital heart diseases are at higher risk. When infective endocarditis is established in a very young individual, and when the aortic valve is involved, simple aortic valve replacement is not always feasible. We describe a successful application of Konno procedure in a small child with pneumococcal infective endocarditis involving the aortic valve and the ascending aorta.

A 12-month-old infant weighing 6.5 Kg, who had undergone closure of a ventricular septal defect at the age of 4 months, presented herself with sore throat and high fever. She developed meningitis in 4 days, and endocarditis within a week after presentation. Blood and spinal fluid culture was positive with *Streptococcus pneumoniae*. Although the cultures became negative after intravenous administration of penicillin, persistent fever did not disappear, and her hemodynamics became unstable. Echocardiography demonstrated severe aortic valve insufficiency, a large mobile vegetation attached to the non-coronary cusp, and dilatation of the left ventricle. A large aneurysm involving sinus of Valsalva above the right coronary cusp and the ascending aorta was noticed at 4 weeks after presentation (Figure 1). These findings lead us to prompt surgical management.

A 5 mm EPTFE graft (W.L.Gore and Associates, Flagstaff, AZ) was anastomosed to the right femoral artery for arterial return from the cardiopulmonary bypass. Median sternotomy was then conducted without incidence. A large aortic aneurysm, occupying the lower half of the ascending aorta, expanding to the side of the main pulmonary artery, was noted. Cardiopulmonary bypass was established with two separate venous cannulas in the vena cavae. The patient was cooled down to 20 degrees celsius. Cardioplegia was administered through the coronary sinus. The aneurysm over the anterior wall of the ascending aorta was opened vertically. The aneurysm lacked the endothelial lining. The right coronary cusp had been totally destroyed, and there was a large vegetation attached to the non-coronary cusp. The right coronary artery originated high above the non-coronary sinus. A second cardioplegia was administered through the coronary ostia. The incision over the aneurysm was extended to the right

sinus, and then to the right ventricular outflow tract. Interventricular septum was also incised over the right sinus. The aneurysm and the aortic valve leaflets were excised. Approximately half the circumference of a AP 16 mm ATS Medical valve (ATS Medical Inc, Mineapolis, MN) was sewn into the remaining aortic annulus. A piece of Dacron (C.R. Bard, Haverhill, PA) graft was sewn to the rest of the sewing ring. The interventricular septum and the anterior wall of the aorta were covered with the graft. The right ventricular outflow tract was reconstructed with a piece of equine pericardium. The patient's recovery was uneventful. No significant hemolysis was noted with the 16 AP ATS valve in the aortic position, and the inflammatory process was suppressed successfully after operation.

Comment

Pneumococcal endocarditis is infrequently seen after introduction of Penicillins. A relatively small number of children with pneumococcal endocarditis have been reported lately [1]. In the present case, sepsis and meningitis were controlled with appropriate antibiotics, but the invasive nature of the disease introduced a large vegetation, and destruction of the aortic wall, as well as aortic insufficiency, in a short period of time. Standard aortic valve replacement was not possible because of the small size of the patient.

Ross procedure could have been an option for this patient [2], but we hesitated to harvest the pulmonary artery, which was in direct proximity to the inflammatory process of the ascending aorta, and the dissection around the pulmonary artery was practically difficult. The use of a homograft to replace the aortic root in patients with infective endocarditis was another option, and has been reported with successful results [3]. However, a homograft is currently not available in Japan.

The Konno procedure was originally developed for the patients with small aortic annuli or narrow left ventricular outflow tracts. Its long-term results have been reported to be excellent. Its successful application to the infective endocarditis, in the native aortic valve or aortic root graft, has been reported in some adult cases [4, 5]. Mavroudis and associates have applied a modification of this technique by extending the aortic incision to the membranous septum in a 6-year-old child [6]. We used the Konno procedure successfully in a 12-month-old patient with pneumococcal

infective endocarditis invading the aortic valve and the ascending aorta. Good exposure and adequate debridement was possible with the procedure. It also accepted a 16 AP ATS Medical valve with an excellent postoperative hemodynamics. In the present case, we consider this procedure to be a good surgical option for a small child with endocarditis involving the aortic valve, especially when the native pulmonary valve is infected and a homograft is not available.

References

1. Citak M, Rees A, Mavroudis C. Surgical management of infectious endocarditis in children. *Ann Thorac Surg* 1992;54:755-60
2. Joyce F, Tingleff J, Pettersson G. Expanding indications for the Ross operation. *J Heart Valve Dis* 1995;4:352-63
3. Riberi A, Caus T, Masena T, et al. Aortic valve or root replacement with cryopreserved homograft for active infectious endocarditis. *Cardiovasc Surg* 1997;5:579-83
4. Black MD, Walley VM, Keon WJ. Fibrous skeleton endocarditis: repair using Konno procedure. *Ann Thorac Surg* 1994;57:225-8
5. Ketosugbo AK, Basu S, Greengart A, et al. Aortoventriculoplasty in the management of an infected Cabrol graft. *Ann Thorac Surg* 1992;53:898-900
6. Mavroudis C, Wampler J, Hodsden JE, Rees AH, Solinger RE, Elbl F. Modified aortoseptoplasty for annular abscess and erosion of the membranous septum. *Chest* 1984;85:442-4

Legends

Fig 1.

Echocardiography revealed aortic insufficiency with a dilated left ventricle. It also showed an aneurysm on the anterior wall of the ascending aorta and mobile vegetation attached to the right coronary cusp. (A) Long axis view. The arrows indicate the aneurysm in the ascending aorta. (B) Short axis view. Vegetation on the aortic valve is shown. The small arrows indicate the aneurysm.

Figure 1 A

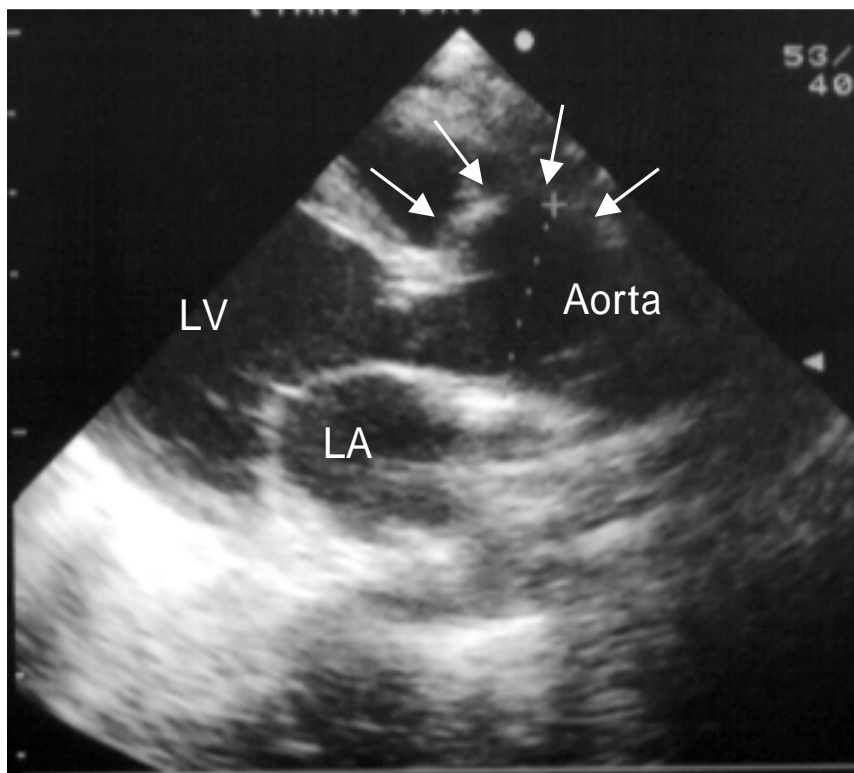


Figure 1 B

