



Asahikawa Medical College Repository <http://amcor.asahikawa-med.ac.jp/>

AMERICAN JOURNAL OF OPHTHALMOLOGY (2001) 131(3):324-331.

Multilayered amniotic membrane transplantation for severe ulceration of the cornea and sclera

Hanada K, Shimazaki J, Shimmura S, Tsubota, K

# Multilayered Amniotic Membrane Transplantation for Severe Ulceration of the Cornea and Sclera

Kazuomi Hanada, MD, Jun Shimazaki, MD, Shigeto Shimmura, MD, and Kazuo Tsubota, MD

From the Department of Ophthalmology, Tokyo Dental College, Chiba, Japan.

The authors do not have any proprietary interest in the products mentioned.

Reprint requests to Kazuomi Hanada, Department of Ophthalmology, Tokyo Dental College, 5-11-13 Sugano, Ichikawa-shi, Chiba, 272-0824 Japan.

## Abstract

### Objective:

To examine the efficacy of amniotic membrane transplantation in the treatment of deep corneal and scleral ulcers.

### Design:

Retrospective, noncomparative case series.

### Participants:

A total of 11 patients were recruited for this study: four patients (4 eyes) with corneal perforation, 5 patients (5 eyes) with a deep corneal ulcer and descemetocoele, and 2 patients (2 eyes) with a scleral ulcer.

### Intervention:

Ulcers were treated by amniotic membrane transplantation. Separate amniotic membranes (AM) were transplanted as material to fill the stromal layer (AM filling), as a basement membrane (AM graft), and as a wound cover (AM patch). After surgery, all cases were treated with artificial tears, autologous serum drops, antibiotic eyedrops, topical steroids, and sodium hyaluronate eyedrops.

Main outcome measures:

Repair of ulcer and/or perforation.

Results:

Eight eyes (72.7%) healed with epithelialization in  $16.5 \pm 8.0$  days, with 5 and 3 eyes showing corneal epithelialization and conjunctival epithelialization, respectively. A persistent epithelial defect was noted in 1 eye with corneal ulcer after limbal allograft transplantation for a chemical burn and in 2 eyes with corneal ulcers as a complication of rheumatoid arthritis.

Conclusion:

Multilayered amniotic membrane transplantation is effective for the treatment of deep ulceration of the cornea and sclera. Some cases may be complicated by the presence of corneal limbal dysfunction or immunological problems.

## Introduction

Despite the many medical and surgical approaches that have been developed to treat them, ulcers of the cornea and sclera are still major problems.

Ulceration induced by persistent epithelial defects (PEDs) are often resistant to medical or surgical treatment. When the basement membrane and stromal matrix are damaged, normal wound healing processes cannot proceed and other factors, such as persistent inflammation, may also compromise wound healing. Treatment of ulceration induced by PEDs requires that a healthy

basement membrane be provided inflammation be reduced to promote epithelialization.

Amniotic membrane has long been used as a surgical material for ophthalmic surgery. De Rötth first reported the use of amniotic membrane in conjunctival plastic surgery in 1940<sup>1)</sup>, but it has not appeared again in the literature until recently. The current popularity of using amniotic membrane started when Kim and Tseng reintroduced the procedure in 1995<sup>2)</sup>. Amniotic membrane has a number of indications, both as a graft to replace damaged ocular surface stroma matrix<sup>3)~5</sup> and as a patch to prevent inflammation<sup>6)</sup>. In the present series, we used amniotic membrane to treat severe ulcers secondary to PEDs.

## Subjects and methods

### Patients

Eleven patients (11 eyes; 6 males and 5 females; mean age,  $63.5 \pm 13.1$  years) with severe ulceration of the cornea or sclera were treated by amniotic membrane transplantation (Table 1). Four eyes had corneal perforation, 5 eyes had deep corneal ulcers with descemetocoele, and 2 eyes had scleral ulcers. All eyes had been treated with eyedrops and/or a therapeutic soft contact lens without success. All operation were performed after obtaining informed consent.

### Measurement of tear dynamics and assessment of limbal function

Three out of 11 patients also had dry eye. To assess tear dynamics, the Schirmer value without anesthesia and the tear clearance rate (TCR) were measured 5 minutes after instilling a 10 µl drop of 0.5% fluorescein and 0.4% oxybuprocaine hydrochloride into the conjunctival sac. Patients with a Schirmer value with anesthesia of under 10 mm / 5 min or a product of the Schirmer value times the TCR (Tear Function Index, TFI) of under 34 were diagnosed with dry eye<sup>7)</sup>. The Schirmer value and TCR were not measured in the perforated cases, and dry eye was assessed in the other eye. Limbal function was assessed on the basis of the presence of palisades of Vogt, vascular invasion of the cornea, and severe conjunctivalization of the cornea. Impression cytology was performed in limbal deficiency cases, to detect signs of conjunctivalization.<sup>8)</sup>.

#### Preparation of amniotic membrane

After written consent was obtained, amniotic membrane was obtained during cesarean section in women sero-negative for hepatitis B virus, hepatitis C virus, syphilis, and human immunodeficiency virus. The amniotic membrane with underlying chorion was washed in 0.01 M phosphate-buffered saline (PBS) containing 1 mg / ml of dibekacin sulfate (Panimycin<sup>®</sup>, Meiji Pharmaceutical Co, Tokyo, Japan) and bluntly separated from the placenta. The membrane was then cut into approximately 3 × 3 cm pieces and rinsed in 0.01 M PBS. Each segment was rinsed in 0.5 M dimethyl sulfoxide (DMSO)

dissolved in PBS, and then in 1.0 M and 1.5 M DMSO in PBS, for 5 minutes each. The membrane was placed in a small container filled with 1.5 M DMSO in PBS, and preserved at -80°C until used. All procedures were performed under sterile conditions. Preoperatively, the container with amniotic membrane was thawed at room temperature, and the membrane was rinsed three times in saline and then once in saline containing 1 mg / ml of dibekacin sulfate. The amniotic membrane was separated bluntly from the underlying chorion with forceps during surgery.

### Surgical procedures

Surgery was performed under subconjunctival or sub-Tenon's capsule anesthesia with 2% lidocaine containing 1:1000 000 noradrenaline (Xylocaine E<sup>®</sup>, Fujisawa Pharmaceutical Co., Osaka, Japan). First, the bottom of the ulcer was debrided, and poorly attached epithelium at the edge of the ulcer was removed as bluntly as possible. After the ulcer surface was treated and healthy corneal or scleral stroma was exposed, the first segment of amniotic membrane was transplanted as filling material in the stromal layer (AM filling). The AM was cut into small pieces and stuffed into the ulcer. In the scleral ulcer cases, the ulcer was filled with auto-Tenon's capsule tissue. The second amniotic membrane was transplanted as a basement membrane (AM graft). Amniotic membrane was placed on the ulcer and secured with 10-0 nylon sutures. The third amniotic membrane was transplanted as a cover (AM patch) with 10-0 nylon or 8-0 vicryl sutures. The AM patch was placed on the

entire wound and corneal limbus to protect the area of re-epithelialization (Figure 1).

### Postoperative management

Postoperatively, antibiotic eyedrops, steroid eyedrops, and sodium hyaluronate eyedrops were instilled. In eyes without dry eye, 0.3% ofloxacin eyedrops (Tarivid<sup>®</sup>, Santen Pharmaceutical Co., Osaka, Japan), 0.1% dexamethasone eyedrops (Sanbetasone<sup>®</sup>, Santen), and 0.1% sodium hyaluronate eyedrops (Hyalein 0.1<sup>®</sup>, Santen) were instilled five times a day. In the dry eye cases, all eyedrops were preservative-free, and included 0.3% ofloxacin eyedrops (Tarivid<sup>®</sup>), 1% methylprednisolone eyedrops (made from Solu-medrol<sup>®</sup>, Pharmacia and Upjohn, Tokyo, Japan), and 0.1% sodium hyaluronate eyedrops (Hyalein-Mini 0.1<sup>®</sup>, Santen) instilled five times a day. During the same period, autologous serum drops<sup>9)</sup> and artificial tears (Soft-santear<sup>®</sup>, Santen) were instilled ten times a day.

### Results

Eight eyes (72.7%) healed with epithelialization in  $16.5 \pm 8.0$  days (Table 2). Three of the eyes with corneal perforation (Cases 1-3) and 2 eyes with descemetocoele (Cases 5 and 6) exhibited corneal epithelialization. One eye with descemetocoele (Case 7), caused by PED after limbal allograft

transplantation (allo-LT) for Stevens-Johnson syndrome, developed conjunctivalization because of poor corneal limbal function. Both eyes with scleral ulcer (Cases 10 and 11) were successfully epithelialized by conjunctiva. AM transplantation failed in three eyes. Case 4, in which there was a large perforation after allo-LT for a chemical burn, developed PED which did not respond to medical treatment. The patient had poor limbal function with severe dry eye and was eventually treated with a conjunctival patch. Two other eyes (Cases 8 and 9) with rheumatoid arthritis (RA)-related peripheral corneal ulcers also developed PED. Despite intensive medical therapy and immunosuppression with systemic cyclosporin A and corticosteroids, these cases required penetrating keratoplasty (PKP). Infection was suspected in one eye. In Case 2, inflammation was observed in the anterior chamber 4 weeks after surgery. Topical 0.5 % amikacin sulfate (Amikacin<sup>®</sup>, Banyu Pharmaceutical Co., Tokyo, Japan), 2.5 % vancomycin hydrochloride (Vancomycin<sup>®</sup>, Shionogi Pharmaceutical Co., Osaka Japan), 1% sulbenicillin sodium (Sulperin<sup>®</sup>, Senju Pharmaceutical Co., Osaka, Japan), and 0.5 % cefmenoxime hemihydrochloride (Bestron<sup>®</sup>, Senju) were used ten times a day. The inflammation resolved after 5 days (Table 2).

## Case 1

A 56-year-old man was treated by an ophthalmologist for an iron foreign body in his right eye in March 1998. One month after removal of the foreign body, an ulcer still persisted and perforation occurred, and the

patient was referred to our clinic on April 28, 1998. The initial examination revealed a corrected visual acuity in the right eye of 20/200. The cornea was perforated and aqueous humor was leaking and there was iris herniation (Figure 2a). We applied surgical adhesive glue and a therapeutic soft contact lens for a month, but the ulcer did not heal. Multilayered AM transplantation was performed on May 29, 1998, and the corneal surface totally epithelialized within 7 days. The sutures in the AM graft were removed after 1 month, at which time there was no leakage of the aqueous humor and intraocular pressure was normal. At 60 weeks after surgery, corrected visual acuity in the right eye was 20/40. The AM filling remained in the stroma, and the AM graft functioned as a basement membrane, while maintaining semi-transparency (Figure 2b).

## Case 5

An 81-year-old woman was treated for chemical injury of the cornea with PKP on her right eye in 1992. Four years after PKP, the graft underwent endothelial rejection, and bullous keratopathy with PED occurred. The patient had no light perception in her right eye because of glaucoma. Medical treatment consisted of 0.3% ofloxacin eyedrops, 1% methyl-prednisolone eyedrops and 0.1% hyaluronate sodium eyedrops five times a day with autologous serum drops ten times a day was started. However, the cornea thinned, and the PED eventually developed a desmetocele (Figure 2c).

Multiple layered AM transplantation was performed on August 19, 1998. Within 29 days after surgery, the corneal surface had totally epithelialized, and corneal thickness was restored (Figure 2d). PED has not recurred to date.

## Case 6

A 75-year-old man suffered corneal peripheral ulcers in both eyes in February 1998. He was referred to our clinic one week later with a diagnosis of bilateral Mooren's ulcer, at which time the ulceration had expanded from the margin to the center of the cornea. The patient also had primary open-angle glaucoma and cataracts in both eyes. He had undergone trabeculectomy in both eyes 10 years earlier. The initial examination revealed a corrected visual acuity in his right eye of 20/2000, and his left eye had no light perception. He was initially treated medically with 0.3% ofloxacin eyedrops, 1% methylprednisolone eyedrops, and 0.1% hyaluronate sodium eyedrops, five times a day, and autologous serum drops ten times a day. During the same period, we prescribed oral cyclosporin 5 mg/kg (Sandimmun<sup>®</sup>, Novartis Pharma Co., Tokyo, Japan). After 6 months, the ulceration in the right eye showed corneal epithelialization, but the left eye had not healed. The corneal ulcer persisted with corneal opacity and ciliary injection (Figure 2e), and on October 15, 1998 multiple layered AM transplantation was performed in order to prevent corneal perforation. Within 10 days after surgery, the corneal surface had totally epithelialized, the inflammation was suppressed (Figure 2f), and the patient was relieved of pain.

## Discussion

### Effect of amniotic membrane transplantation

Previous reports have demonstrated that the AM has unique properties, including antibacterials, wound protecting, pain reducing, epithelialization promoting, and fibrosis suppressing effects<sup>10)~14)</sup>. These properties are considered suitable for the treatment of impaired epithelialization of the ocular surface. Lee and Tseng used AM for the treatment of PED, and it healed in 91% of their patients<sup>6)</sup>. Their success may be attributed by inhibition of collagenase by AM, and supplementation of the basement membrane and growth factors. In addition to taking advantage of these properties in the present study, AM was also used to supplement the collagen layer. A combination of collagen layer supplementation, basement membrane reconstruction, and promotion of epithelialization and wound healing is required to treat severe ulceration. We used multi-layered AM transplantation to achieve these goals. AM filling provides a substitute for collagens, the AM graft provides basement membrane for proper epithelialization, and the AM patch protects the wound. Kruse et al reported the efficacy of AM graft for deep corneal ulcer to supply stromal layer<sup>15)</sup>. We found that 8 out of 11 eyes (72.7%) were successfully treated by this method with a mean epithelialization period of  $16.5 \pm 8.0$  days. Leakage of aqueous humor was cured in 5 eyes, and the corneal/scleral stroma regained its original thickness.

No recurrence of PEDs was observed in the mean follow-up period of  $42.3 \pm 15.2$  weeks. These results suggested that if signs of infection are negative, AM can be used not only to treat corneal ulcers, but corneal and scleral perforation as well.

The results in the failed cases suggest that AM transplantation may not be useful in cases with total limbal deficiency or with autoimmune disorders.

The basement side of the AM is an ideal substrate for supporting the growth of epithelial progenitor cells by prolonging their life span and maintaining their clonogenicity<sup>16)</sup>. AM transplantation can be used to expand remaining limbal stem cells and corneal transient amplifying cells during the treatment of partial limbal deficiency<sup>17)</sup>. However, this specific action is not effective when there are no stem cells, and limbal transplantation may be needed<sup>18)</sup>.

Ulceration due to autoimmune disease has to be treated carefully as well.

Although one case of Mooren's ulcer was successfully treated, 2 eyes with RA-related corneal ulcer developed PED postoperatively. A primary immunologic disturbance with production of autoantibodies against conjunctival and corneal tissue may be the reason for this, and control of the immunological imbalance should precede amniotic membrane transplantation in these conditions.

## Comparison with other surgical methods

Conservative management, such as continuous pressure patching with ointment, heals most cases of corneal epithelial defects. However, cases with

PED require more extensive procedures. Medical therapy with preservative-free lubricants as the most suitable agents is the treatment of first choice.

Topical steroids may be chosen to reduce inflammation, but they should be used carefully. The continuous use of a therapeutic soft contact lens promotes the healing of epithelial defects<sup>19)</sup>. In cases that do not respond to a medical approach, a surgical procedure is required.

Surgical adhesive glue is sometimes used to fill small corneal perforations<sup>20)</sup>, but it cannot replace the total thickness of the corneal stroma or sclera. The effect of adhesion is not permanent, and it sometimes delays normal wound healing and epithelialization. In the past, conjunctival transplantation or conjunctival cover was frequently used in an emergency, but it can cause neovascularization, fibrosis, and proliferation of abnormal epithelium.

Inflammation and invading vessels caused by conjunctival tissue may be a risk factor in further treatment, such as PKP or other ocular surface reconstructions.

A donor cornea may be the most suitable material for grafting to treat a damaged cornea. PKP and LKP are commonly used to treat corneal ulceration<sup>21)</sup>, but both require donor tissue. In emergencies, it is sometimes too late by the time a donor is found, especially in Japan, where the donor cornea supply is small. There is also the risk of rejection after surgery because of the donor cornea's immunogenicity. Ulceration often induces PED or persistent inflammation, which may increase the risk of graft failure.

## Complications and their treatment

In Case 2 , inflammation was observed in the anterior chamber 4 weeks after surgery, but it resolved after 5 days in response to frequent use of antibiotic eyedrops. The AM was preserved in clean condition, and all AM cultured at operation use was negative. Organisms cultured were negative, however, microbial keratitis was suspected. To prevent postoperative infection and achieve epithelialization, it is important to debride the bottom of the ulcer and poorly attached epithelium at the edge of the ulcer. AM transplantation should also be avoided in cases with active infection. A cornea totally covered with AM makes observation of the anterior chamber or fundus difficult because of its lack of transparency, there is the risk of overlooking signs of infections or inflammation.

In summary, we found that AM transplantation can reconstruct severe ulcers of the cornea and sclera. The unique characteristics of amniotic membrane appear to offer a new surgical approach to ocular surface diseases. We recognize that cases with total limbal dysfunction or autoimmune disorder are not cured by AM transplantation alone. Our series is based on the excellent ideas of predecessors, however, the entire mechanism of the healing effect of amniotic membrane is still unknown. Further studies are needed to understand the mechanisms involved in the benefits of AM on the ocular surface.

## References

- 1 de Rötth A. Plastic repair of conjunctival defects with fetal membranes. *Arch Ophthalmol* 1940;23:522-525.
- 2 Kim JC, Tseng SCG. Transplantation of preserved human amniotic membrane for surface reconstruction in severely damaged rabbit corneas. *Cornea* 1995;14:472-484.
- 3 Tsubota K, Satake Y, Ohyama M, et al. Surgical reconstruction of the ocular surface in advanced ocular cicatricial pemphigoid and Stevens-Johnson syndrome. *Am J Ophthalmol* 1996;122:38-52.
- 4 Shimazaki J, Yang H-Y, Tsubota K. Amniotic membrane transplantation for ocular surface reconstruction in patients with chemical and thermal burns. *Ophthalmology* 1997;104:2068- 2076.
- 5 Shimazaki J, Shinozaki N, Tsubota K. Transplantation of amniotic membrane and limbal autograft for patients with recurrent pterygium associated with symblepharon. *Br J Ophthalmol* 1998;82:235-240.
- 6 Lee SH, Tseng SCG. Amniotic membrane transplantation for persistent epithelial defects with ulceration. *Am J Ophthalmol* 1997;123:303-312.
- 7 Xu K, Yagi Y, Toda I, Tsubota K. Tear function index: a new measure of dry eye. *Arch Ophthalmol* 1995; 233:1-7.
- 8 Puuangsricharem V, Tseng SCG. Cytologic evidence of corneal diseases with limbal stem cell deficiency. *Ophthalmology* 1995;102:1476-1485.

- 9 Tsubota K, Goto E, Fujita H, et al. Treatment of dry eye by autologous serum application in Sjögren's syndrome. *Br J Ophthalmol* 1999; 83: 390-395
- 10 Trelford JD, Trelford-sauder M. The amnion in surgery, past and present. *Am J Obstet Gynecol* 1979;134:833-845.
- 11 Colucho G, Graham WP, Greene AE, et al. Human amniotic membrane as a physiologic wound dressing. *Arch Surg* 1974;109:370-373.
- 12 Prasad JK, Feller I, Thompson PD. Use of amnion for the treatment of Stevens-Johnson syndrome. *J Trauma* 1986;26:945-6.
- 13 Subrahmanyam M. Amniotic membrane as a cover for microskin grafts. *Br J Plast Surg* 1995;48:477-478.
- 14 Talmi YP, Finckelstein Y, Zohar Y. Use of human amniotic membrane as a biologic dressing. *Eur J Plast Surg.* 1990;13:160-162.
- 15 Kruse FE, Rohrschneider K, Völcker HE. Multilayer amniotic membrane transplantation for reconstruction of deep corneal ulcers. *Ophthalmology.* 1999;106:1504-1511.
- 16 Meller D, and Tseng SCG. In vitro conjunctival epithelial differentiation on preserved human amniotic membrane. *Invest Ophthalmol Vis Sci (suppl)*39:#428, 1998.
- 17 Tseng SCG, Prabhasawat P, Barton K, et al. Amniotic membrane transplantation with or without limbal allografts for corneal surface

- reconstruction in patients with limbal stem cell deficiency. Arch Ophthalmol 1998;116:431-441.
- 18 Tsubota K, Satake Y, Kaido M, et al. Treatment of severe ocular surface disorders with corneal epithelial stem-cell transplantation. N Engl J Med 1999;340:1697-1703.
  - 19 Aquavella JA. Therapeutic contact lenses. In Aquavella JA and Rao GN, Contact Lenses. Philadelphia: Lippincott 1987:140-163.
  - 20 Boruchoff SA, et al. Clinical applications of adhesives in corneal surgery. Trans. Am. Acad. Ophthalmol. Otolaryngol 1969;73:499.
  - 21 Dohlman CH, Boruchoff SA, Sullivan GL. A technique for the repair of perforated corneal ulcers. Arch Ophthalmol. Otolaliningol;73:471.

## Figure 1

Surgical steps in multilayered amniotic membrane transplantation.

(a) The first amniotic membrane is cut into small pieces and pushed into the ulcer (arrows). The second amniotic membrane is placed on the ulcer and secured with 10-0 nylon sutures.

(b) The third amniotic membrane is transplanted as a cover (arrows).

(c) Surgical schema. Note the amniotic membrane pushed into the ulcer as a filling material in the stromal layer (AM filling), placed on ulcer as a basement membrane (AM graft), and on the entire of wound as a cover (AM patch).

## Figure 2

- (a) Preoperative appearance of case 1. The cornea is perforated, aqueous humor is leaking, and the iris is herniated.
- (b) Postoperatively, there is no leakage of aqueous humor. The AM filling remains in the stroma. The AM graft is functioning as a basement membrane, while maintaining transparency.
- (c) Case 5. Descemetocoele is seen preoperatively.
- (d) Corneal surface is totally epithelialized after surgery, and corneal thickness is restored.
- (e) Case 6. An ulcer with persistent epithelial defect is seen at the corneal margin preoperatively.
- (f) Corneal surface is totally epithelialized after surgery.

K. Hanada, et al.

Table 1

Patient profile

case	age (y)	Sex	underlying disease	other complications	cornea/sclera	size of ulcer (mm)	condition	previous surgery	prior treatment	dry eye condition	limbal dysfunction
1	56	M	foreign body		cornea	3x3	microperforation		CL, surgical adhesive	no	no
2	47	M	foreign body		cornea	3x3	microperforation		CL, surgical adhesive	no	no
3	79	F	trichiasis	leukoma, band kerat	cornea	6x3	microperforation		CL, surgical adhesive, Ts	yes	no
4	48	M	chemical burn	glaucoma	cornea	5x4	rupture	allo-LT+AM graft+Ts	systemic steroid and cycl	yes	yes
5	81	F	bullous keratopathy	glaucoma	cornea	5x5	desmetocele	PKP	CL	no	no
6	74	M	Mooren's ulcer	glaucoma	cornea	6x2	desmetocele		systemic steroid and cycl	no	no
7	54	M	SJS, post LT	glaucoma	cornea	4x4	desmetocele	allo-LT+AM graft+Ts	systemic steroid and cycl	yes	yes
8	54	F	RA, post LKP	leucoma	cornea	6x6	desmetocele	LKP	systemic steroid and cycl	no	no
9	67	F	RA, post LKP		cornea	6x6	desmetocele	LKP	systemic steroid and cycl	no	no
10	75	M	pterygium	cataract	sclera	2x2	microperforation	pterygium excision (MMC)		no	no
11	58	F	foreign body	glaucoma, cataract	sclera	6x3	microperforation		conjunctival cover, Ts	no	no

SJS: Stevens-Johnson syndrome

RA: rheumatoid arthritis

allo-LT: allograft limbal transplantation

AM graft: Amniotic membrane graft

PKP: penetrating keratoplasty

LKP: lamellar keratoplasty

MMC: mitomycin C used intraoperative

CL: therapeutic soft contact lens

Ts: tarsorrhaphy

K. Hanada, et al.

Table 2

# Amniotic Membrane Transplantation results

case	ow up	(ntivstoperative BC\	epithelialized with	elization (complications	veatment, final BCVA	
1	60	) /2(	20/40	cornea	7	
2	22	) /1(	20/20	cornea	16	ypopion (4 wks of antibiotics, 20/20
3	64	LP+	HM	cornea	18	
4	43	LP+	*		*	PED (5 wk) juncival patching, LP+
5	36	LP-	LP-	cornea	29	
6	32	LP-	LP-	cornea	15	
7	46	LP-	LP-	conjunctiva	10	
8	37	HM	*		*	PED (13 wk) ECCE+IOL. 20/200
9	40	HM	*		*	PED (20 wk) PKP, 20/40
10	50	) /1(	20/100	conjunctiva	10	
11	28	/20	20/2000	conjunctiva	27	

BCVA: best corrected visual acuity

LP: light perception

HM: hand motions

PED: persistent epithelial defect

ECCE+IOL: extracapsular cataract extraction and intraocular lens implantation

case	follow up (wk)	preoperative BCVA	postoperative BCVA
1	60	20/200	20/40
2	22	20/100	20/20
3	64	LP+	HM
4	43	LP+	LP+
5	36	LP -	LP -
6	32	LP -	LP -
7	46	LP -	LP -
8	37	HM	HM
9	40	HM	HM
10	50	20/100	20/100
11	28	20/2000	20/2000

CVA: best corrected visual acuity  
LP:light perception

epithelialized with	epithelization (days)	complications (wk)
cornea	7	
cornea	16	hypopion (4 wk)
cornea	18	
	(failed)	PED (5 wk)
cornea	29	
cornea	15	
conjunctiva	10	
	(failed)	PED (13 wk)
	(failed)	PED (20 wk)
conjunctiva	10	
conjunctiva	27	

CVA: best corrected visual acuity  
LP: light perception

other treatment, final BCVA

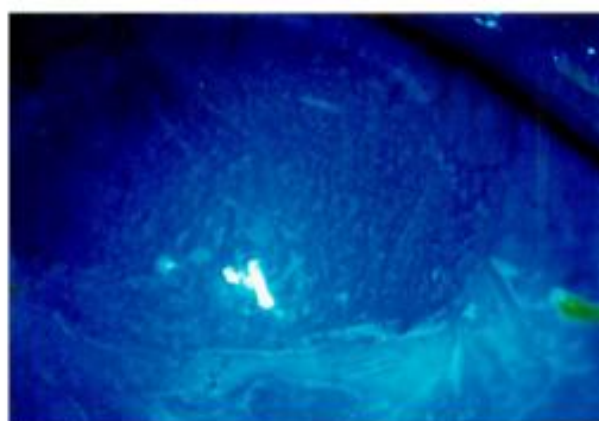

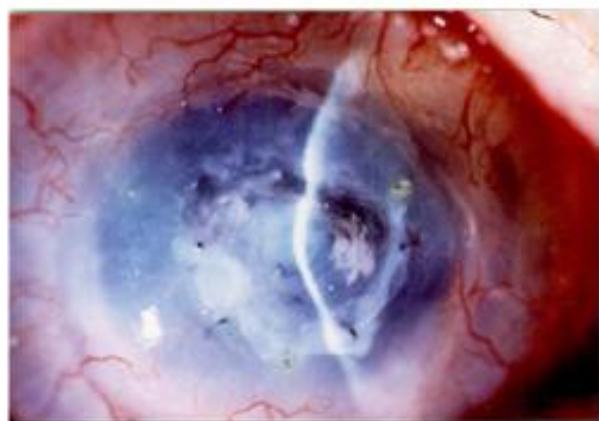
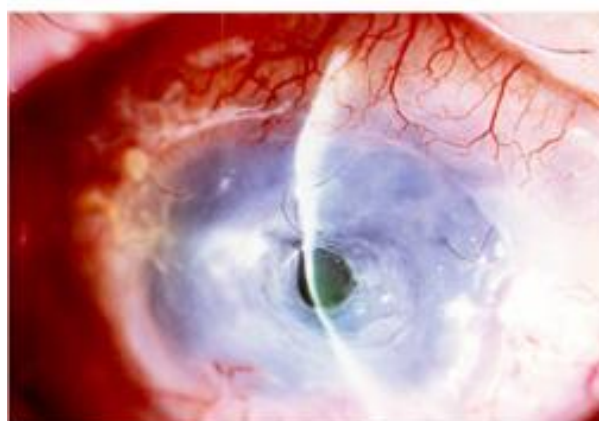
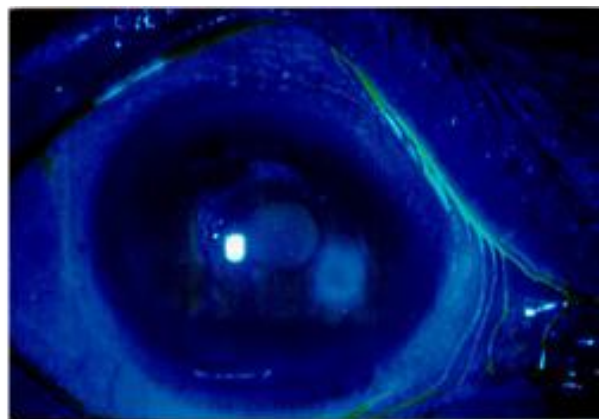
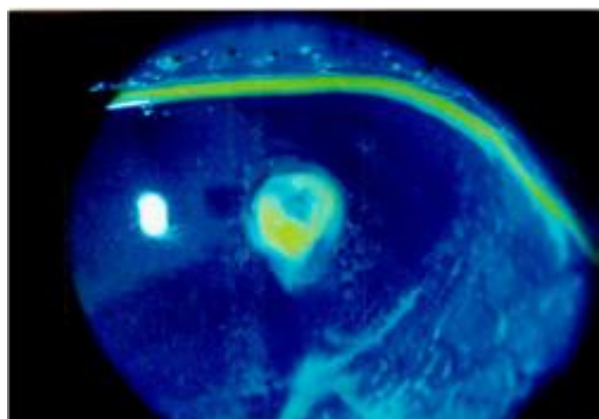
requent use of antibiotics, 20/20

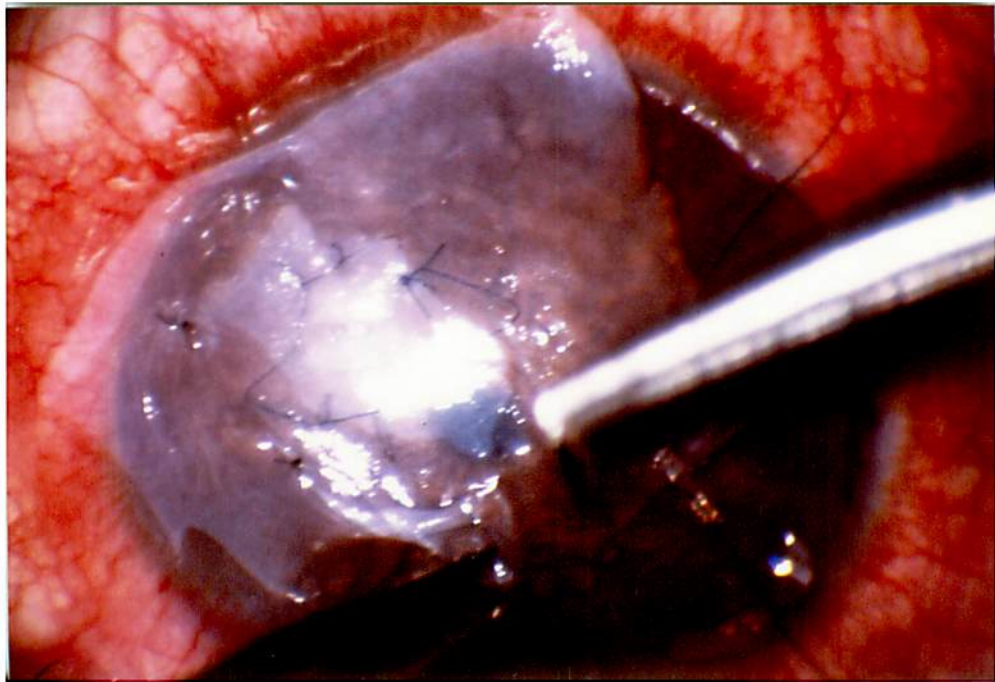uto-conjunctival patching, LP+

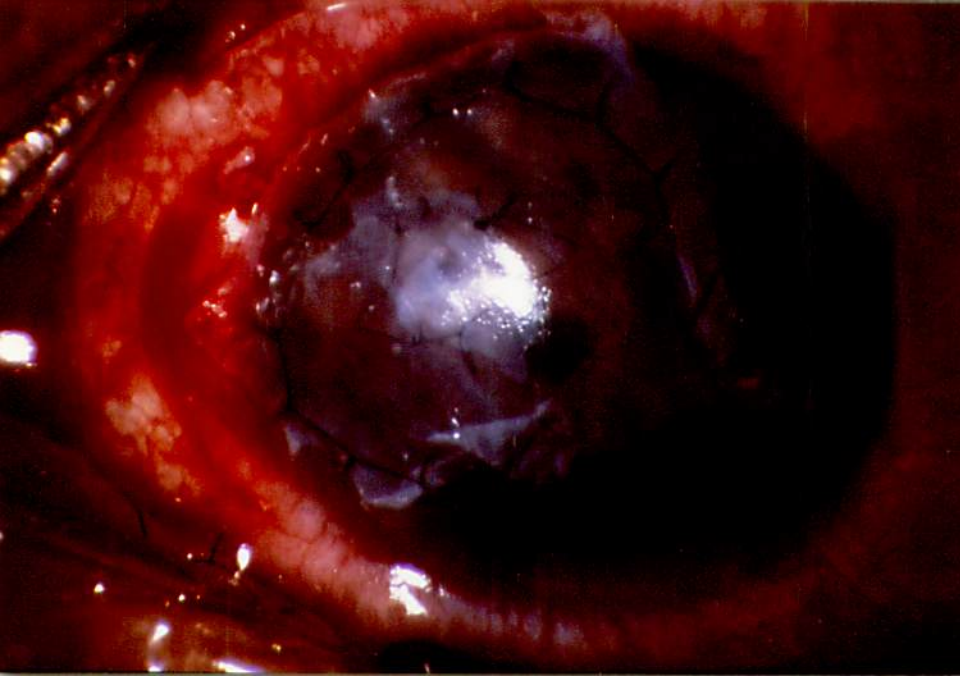
PKP+ECCE+IOL. 20/200

PKP, 20/40

CVA: best corrected visual acuity  
LP:light perception







AM patch  
AM graft

10-0 nylon suture



K.Hanada, et al.  
Figure 1c